



Synergistic Effects of Sublethal Concentrations of Cadmium and Zinc on Mortality, Growth and on Gills and Hepatopancreas Histological Structure of *Litopenaeus vannamei* Postlarvae

Martín G. Frías-Espéricueta¹, Selene M. Abad-Rosales², Areli Vargas-Jiménez¹, Tania Sarabia-Espinoza¹, Beatriz A. Rodríguez-Salas¹, Isidro Osuna-López¹, Domenico Voltolin^{1,3,*}

¹ Facultad de Ciencias del Mar, Universidad Autónoma de Sinaloa, P.O. Box 1132, Mazatlán, Sinaloa, CP 82000 Mexico.

² Centro de Investigación en Alimentación y Desarrollo, Unidad Mazatlán, Av. Sábalo-Cerritos S/N, Mazatlán, Sinaloa, CP 82010, Mexico.

³ Centro de Investigaciones Biológicas del Noroeste, Laboratorio UAS-CIBNOR, P.O. Box 1132, Mazatlán, Sinaloa, CP 82000 Mexico.

* Corresponding Author: Tel.: +52.669 9828656.; Fax: +52.669 9828656.;
E-mail: voltolin04@cibnor.mx

Received 27 October 2015
Accepted 17 April 2016

Abstract

Litopenaeus vannamei postlarvae were exposed during 4 weeks to progressively increasing sublethal concentrations of cadmium and zinc (Cd: 8.8, 24, 72 and 216 $\mu\text{g L}^{-1}$, Zn: 81, 160, 320 and 640 $\mu\text{g L}^{-1}$), used alone or in mixture, in order to evaluate their joint effect on survival and growth, and on the histological structure of hepatopancreas and gills of the exposed organisms. After exposure to single metals there were no differences between control and treatments in survival and growth, while survival was significantly lower with the highest concentration of the mixture. Growth was also affected and showed a significant dose-related response. No histopathologies were observed in gills of shrimps exposed to single metals, while their hepatopancreas showed moderate to severe changes during the first three weeks. With the mixture, moderate edemas were present in gills lacunae and the hepatopancreas had sloughing of epithelial cells until the third week, but no histological alterations were evident by the end of the experiment. The results of this study show a synergistic effect of the mixture Cd + Zn on survival, growth and histological structure of hepatopancreas and gills of the Pacific white shrimp *L. vannamei*.

Keywords: Metal mixture, synergistic effect, *Litopenaeus vannamei*, growth, histopathology.

Introduction

The Pacific white shrimp *Litopenaeus vannamei* is the most important shrimp for aquaculture worldwide. It is the only species grown commercially in Mexico, where most farms are adjacent to the densely populated fertile Pacific coastal plains, which are used for intensive agriculture. Therefore, the lagoons, estuaries and embayments which are used as water sources for shrimp pond management are likely to receive contaminants of urban, industrial and agricultural origin, which may affect survival, growth, and development of the shrimps in culture (Gunnarsson *et al.*, 2000).

Among these contaminants, several metals are of particular interest because of their persistence and effects on several biochemical pathways and physiological functions. Among these, zinc and cadmium are common and are known for their deleterious effects on aquatic crustaceans (Wu and Chen, 2004, 2005; Barbieri, 2009) and it has been shown that, although *L. vannamei* may regulate its internal Zn concentration, the combination of Zn with other metals may have synergic or antagonistic effects (Nuñez-Nogueira *et al.*, 2012). These effects should

be studied in detail, because different organisms and even different tissues of the same organism may show different responses to metal mixtures (Norwood *et al.*, 2003; Serafim and Bebianno, 2010).

Several studies have reported histopathological effects of metals in *L. vannamei*. After exposure to copper, effects such as necrosis and loss of regular structure in gills and hepatopancreas, respectively, were observed by Frías-Espéricueta *et al.* (2008). In other studies, three weeks exposure to a mixture of metals (Cd, Cu, Fe, Hg, Mn, Pb and Zn) caused significant reduction of R cell and abnormal dilation of the lacunae was reported in hepatopancreas and gills, respectively (Frías-Espéricueta *et al.*, 2008), while Wu *et al.* (2008) reported moderate vacuolization in hepatopancreas tubules when exposed to an essential metal (Zn) and Usman *et al.* (2013) observed multiple hyperplasia in gills after exposure to lead.

The aim of the current study is to report the effect of cadmium, zinc and of their mixture on survival, growth and histological structure of the gills and hepatopancreas of *L. vannamei* postlarvae exposed during 28 days to different sublethal concentrations of these metals and of their mixture.

Materials and Methods

The experimental organisms were *L. vannamei* postlarvae obtained from a local hatchery ten days after molting from mysis 3 to postlarva (postlarval stage PL₁₀). Acclimation to the test conditions lasted three days in a 100 L common stocking tank with 90 L of seawater obtained from Mazatlán Bay which was filtered through a sand and gravel bed and one cartridge system of 10, 5 and 1- μ m and treated with activated charcoal. Holding conditions were 12: 12 hours light: dark photoperiod, twice daily feeding *ad libitum* with *Artemia* sp. nauplii, continuous aeration and 90% water replacement every 24 hours. Due to space constraints, the effects of each metal and of their mixture were determined in separate experiments with different batches of postlarvae.

After acclimation, groups of 20 postlarvae collected at random from the stocking tank were placed in each of 15 1-L plastic beakers for three additional days and maintained under the same conditions as in the common tank. The experiment started at the end of this second acclimation and lasted four weeks, during which each metal concentration was tested in triplicate. Three containers without metal served in each case as controls.

The test solutions were prepared dissolving CdCl₂ and ZnCl₂ in sterile distilled water. The nominal concentrations for Cd were: 8.8, 24, 72 and 216 μ g L⁻¹, and those for Zn were: 81, 160, 320 and 640 μ g L⁻¹. In each case, the first was equivalent to the value for saltwater of the criterion of continuous concentration (CCC: EPA, 2009) and all values were lower than the known LC₅₀ values for *L. vannamei* postlarvae (2.49 and 2.08 mg L⁻¹ for Cd and Zn, respectively: Frías-Espericueta, *et al.*, 2001, 2003). These were determined in previous experiments with

the traditional 96-h exposure to increasing concentrations of each metal (1-25 mg L⁻¹ for Cd and 1-30 mg L⁻¹ for Zn), calculating the respective LC₅₀ values with the method of probit analysis (Finney, 1971).

For the binary mixtures, shrimps were exposed to the sum of the two respective sublethal concentrations of each metal (Mix1= 8.8 and 81 μ g L⁻¹; Mix2: 24+160 μ g L⁻¹; Mix3: 72+320 μ g L⁻¹; Mix4: 216+640 μ g L⁻¹ of Cd and Zn, respectively) (Table 1).

Throughout the experiments salinity, temperature, dissolved oxygen, pH and total ammonium were 35±0.5 ppt, 26±1 °C, 5.4±0.5 mg L⁻¹, 8.1±0.1 and 5±1 μ g L⁻¹, respectively. The experimental conditions were as in the acclimation period, but with 90% test solutions exchanges at 48 h intervals to maintain metal concentrations (Usman *et al.*, 2013) using the static method with replacement described by Buikema *et al.* (1982) and APHA (1992).

Survival was monitored twice daily: non-motile organisms with no response to stimulation with a glass rod were assumed dead and removed. At the end of the experiment, growth was evaluated measuring 12 organisms for each treatment (four for each triplicate container) to the nearest 0.5 mm from the tip of the rostrum to that of the telson. Given the short duration of the experiment, growth in size was assumed to be linear (López-Martínez *et al.*, 2005; Franco *et al.*, 2006). Therefore, growth rates (GR) were calculated with the equation:

$$GR = (L_f - L_i) t^{-1}$$

where L_f and L_i are the final and initial total length (mm), respectively, and t is the number of days of exposure.

Table 1. Mean and standard deviation of survival (%), final size (cm) and growth rate (mm/day) of *L. vannamei* postlarvae exposed during four weeks to four concentrations of Cd, Zn, and their mixture

Treatment	Survival (%)	Final size (cm)	Growth rate (mm/day)
Zn			
Control	100±0a	2.07±0.18a	0.270±0.061a
80 μ g L ⁻¹	100±0a	2.08±0.16a	0.277±0.059a
160 μ g L ⁻¹	100±0a	1.99±0.15a	0.243±0.016a
320 μ g L ⁻¹	100±0a	1.90±0.11a	0.217±0.040a
640 μ g L ⁻¹	100±0a	1.91±0.20a	0.213±0.068a
Cd			
Control	93±2a	1.45±0.39a	0.206±0.039a
8.8 μ g L ⁻¹	98±3a	2.39±0.16a	0.207±0.038a
24 μ g L ⁻¹	95±0a	1.92±0.75a	0.198±0.027a
72 μ g L ⁻¹	85±9a	1.54±0.54a	0.195±0.032a
216 μ g L ⁻¹	90±5a	1.94±0.49a	0.197±0.031a
Cd+Zn			
Control	98±3b	2.10±0.23c	0.048±0.008b
Mix1	75±9a	1.77±0.34bc	0.044±0.008b
Mix2	87±10ab	1.66±0.22b	0.033±0.010ab
Mix3	87±7ab	1.69±0.30b	0.036±0.008ab
Mix4	68±3a	1.25±0.15a	0.018±0.004a

For each metal treatment, different letters indicate significant differences between data in the same column (one way ANOVA, $\alpha = 0.05$).

At the end of each week, 12 postlarvae of each concentration (four of each container) were injected in the hepatopancreas and in the posterior and interior abdominal segments with Davidson's solution, left 24 h in the same solution, dehydrated in a graded (70-100%) ethanol series, cleared with xylene and embedded in paraffin blocks. These were used to obtain with a microtome 5- μ m sections, which were stained with hematoxylin-eosin (Odendaal and Reinecke, 2007), and observed under a microscope. The degree of histological effects was assessed for each sampling date with the scores of histological damage by Zodrow *et al.* (2004): normal, mild, moderate and severe (0, <25, >75 and 100% of the fields with some degree of histological damage, with respect to the control section of the same sampling date, respectively).

Mean survival, final length and mean growth rates were compared with one-way ANOVA tests, after arcsine square root transformation for survival. The data of final size were not normal in the case of Zn, and their mean values were compared with the Kruskal-Wallis non parametric test. In all cases the level of significance was $\alpha=0.05$, and the differences were determined with multiple comparisons Tukey's or Dunn's tests (Zar, 2009).

Results

There were no significant differences in mortality, final sizes and growth rates after exposure to the four concentrations of Cd and Zn. However, final survival after exposure to the lowest and highest concentrations of the +Zn mixture was significantly lower ($P<0.05$) than that observed in the control cultures, and final sizes and growth rates showed a clear dose-dependent response. No significant difference was observed between control and postlarvae exposed to the sum of the CCC's of the two metals, Mix1, but mean sizes and growth rates tended to decrease progressively, and were significantly ($P<0.05$) lower with the Mix4 mixture (Table 1).

The gills of the postlarvae exposed to the four concentrations of Cd and Zn did not show histopathological alterations throughout the whole experiment. In the hepatopancreas, no alterations were observed after the first and second week of exposure to Zn (Figure 1a), although by the end of the third week 41, 33 and 25% of the postlarvae exposed to 320 and 640 μ g L⁻¹ of Zn had slight, moderate and severe vacuoles reductions (Figure 1b). Organisms exposed to 24 μ g L⁻¹ of Cd during three weeks showed 22, 66 and 12% of slight, moderate and severe vacuole reductions in the hepatopancreas, respectively (Figure 1c). The two higher concentrations (72 and 216 μ g L⁻¹) gave similar results.

Histopathological alterations were more evident

in postlarvae exposed to the mixture: edemas were observed in gills lacunae after the third week of exposure to Mix1 and Mix2, while this histopathology was observed after the second week in 16.7% of the PLs exposed to Mix3 and Mix4 (Figure 2a).

No alterations were observed in the hepatopancreas of postlarvae exposed to Mix1, but after the second week of exposure 16% exposed to Mix3 and 58.3% to Mix4 showed R cells reduction (Figure 2b) and slight sloughing of epithelial cells, respectively. With Mix4, 80% of the organisms showed sloughing of epithelial cells (Figure 2c) and 66.7% showed moderate R cells reduction in the third and fourth week of exposure (Figure 2d), respectively. However, no alterations were observed after the fourth week with all concentrations of the single metals and of their mixture.

Discussion

Our results on the acute effect of the single metals do not agree with the mortalities observed with comparable concentrations by Santos *et al.*, (2000), who reported mortalities of 85% of *Farfantepenaeus paulensis* postlarvae exposed during 5 weeks to Zn concentrations of 525 μ g L⁻¹, and by Wu and Chen (2005), who found that exposure to 400 μ g L⁻¹ of Cd during four weeks caused total mortality of *L. vannamei* postlarvae. In view of the lack of mortality after single metal exposure, the significant difference in survival observed with the Cd + Zn mixture indicates an increase of toxicity and hence a synergistic effect.

An antagonistic effect of Zn and Cd was described in some plant organisms, but it was found to be either concentration dependent (Sharma *et al.*, 1999) or even restricted to some type of tissue (Tkalec *et al.*, 2014). However, these same authors described also synergistic effects, either in different tissues or when one of the toxicants exceeded a critical level. This coincides with the results obtained by Negilski *et al.* (1981), who found that when concentrations of the Cd + Zn mixture were higher than the respective LC50-14d values, mortalities of *Trypaea (Callianassa) australiensis* were lower than those expected using independent dissimilar or simple similar action models (effect on different or on the same target organs or functions, respectively), whereas at low doses (<LC50-14d) they were higher and lower, respectively, than those expected from the two models.

In our case, all concentrations of the mixture were well below LC50-96h, and the results coincide with the intermediate effect between the two models found by Negilski *et al.* (1981), confirming the difficulties inherent in any attempt to model ecotoxicological synergistic effects (Newman and McCloskey, 1996; Norwood Borgmann *et al.*, 2003). Confirming the synergistic effect at low

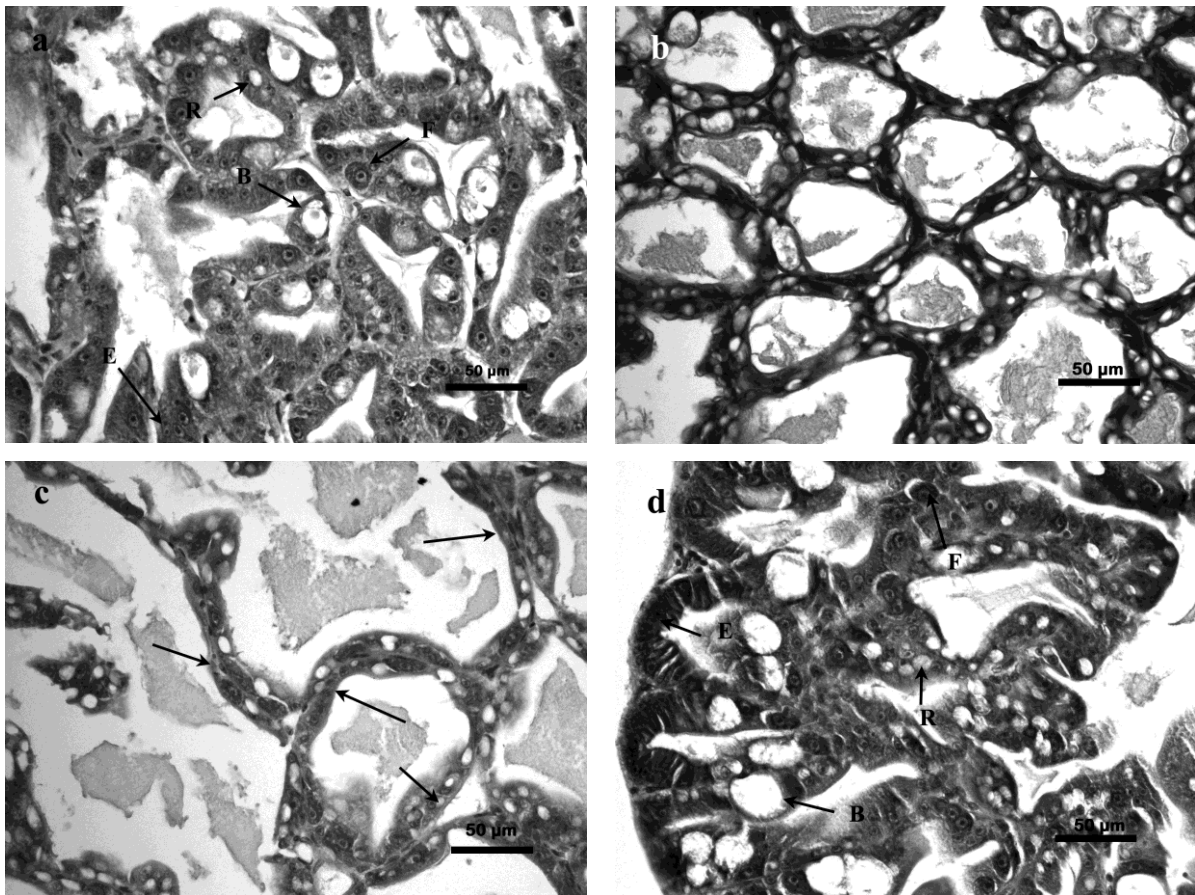


Figure 1. Hepatopancreas. (a) $320 \mu\text{g L}^{-1}$ of Zn first week of exposure. (b) $640 \mu\text{g L}^{-1}$ of Zn third week of exposure: severe reduction of B cells in hepatopancreas. (c) $24 \mu\text{g L}^{-1}$ of Cd third week of exposure: severe reduction of R cells in hepatopancreas (arrow). (d) Control Zn third week of exposure: The capital letters indicate E, F, B and R cells.

concentrations of these metals, our results coincide with those observed by Vanegas *et al.* (1997), who found that the toxicity of the Cd + Zn mixture for *Litopenaeus setiferus* juveniles was higher than the sum of their individual effects.

A negative effect on crustacean growth of single metal exposure to Cd and Zn has been described by several authors: on *P. japonicus* exposed to Cd and Zn by Liao and Hsieh (1988), on *P. monodon* exposed to Cd (Karlson, 1994), and on *F. paulensis* postlarvae exposed to Cu and Zn (Santos *et al.*, 2000). In the case of *L. vannamei*, Wu and Chen (2005) observed delayed growth of postlarvae after 14 days of exposure to $400 \mu\text{g L}^{-1}$ of Cd, and after 7 days when exposed to $600 \mu\text{g L}^{-1}$ of Zn.

A similar result was obtained by Frías-Espéricueta *et al.* (2009), who reported a decrease in final weight of postlarvae exposed to a mixture of Cd, Hg, Pb, Cu, Fe, Mn and Zn, and an inverse relationship between molting frequency and concentration of the mixture, probably due to an energetic imbalance on enzymatic systems to protect cells from the metals' toxic effects (Santos *et al.*, 2000). In this context, Wu *et al.* (2008) reported that the biochemical alterations in the hepatopancreas of *L. vannamei* juveniles exposed

to cadmium and zinc might be the cause of reduced growth.

In view of their involvement in the exchange processes between internal and external environment, gills are considered an important source of entry of waterborne metals such as Cd (Usman *et al.*, 2013; Putranto *et al.*, 2014). However, our results show that, within the concentration range used in this work, this metal has no evident effect on gill structure. This is in agreement with the observations of Soegianto *et al.* (1999) and by Keating, *et al.* (2007), who detected structural alterations in *Marsupenaeus japonicus* exposed to concentrations one order of magnitude higher than those of our experiments, or in *L. vannamei* postlarvae with concentrations higher than the LC50-48h, respectively.

Metals are accumulated in the hepatopancreas because of its function in xenobiotic metabolism, (Wu *et al.*, 2008). This accumulation is likely to cause structural damages, such as the severe alterations described by Chiodi-Boudet *et al.* (2015) in the freshwater shrimp *Palaemonetes argentinus* exposed during 15 days to a Cd concentration equivalent to 50% of the LC50-96h for that species. However, our result obtained with Cd levels equivalent to approximately 10% of the

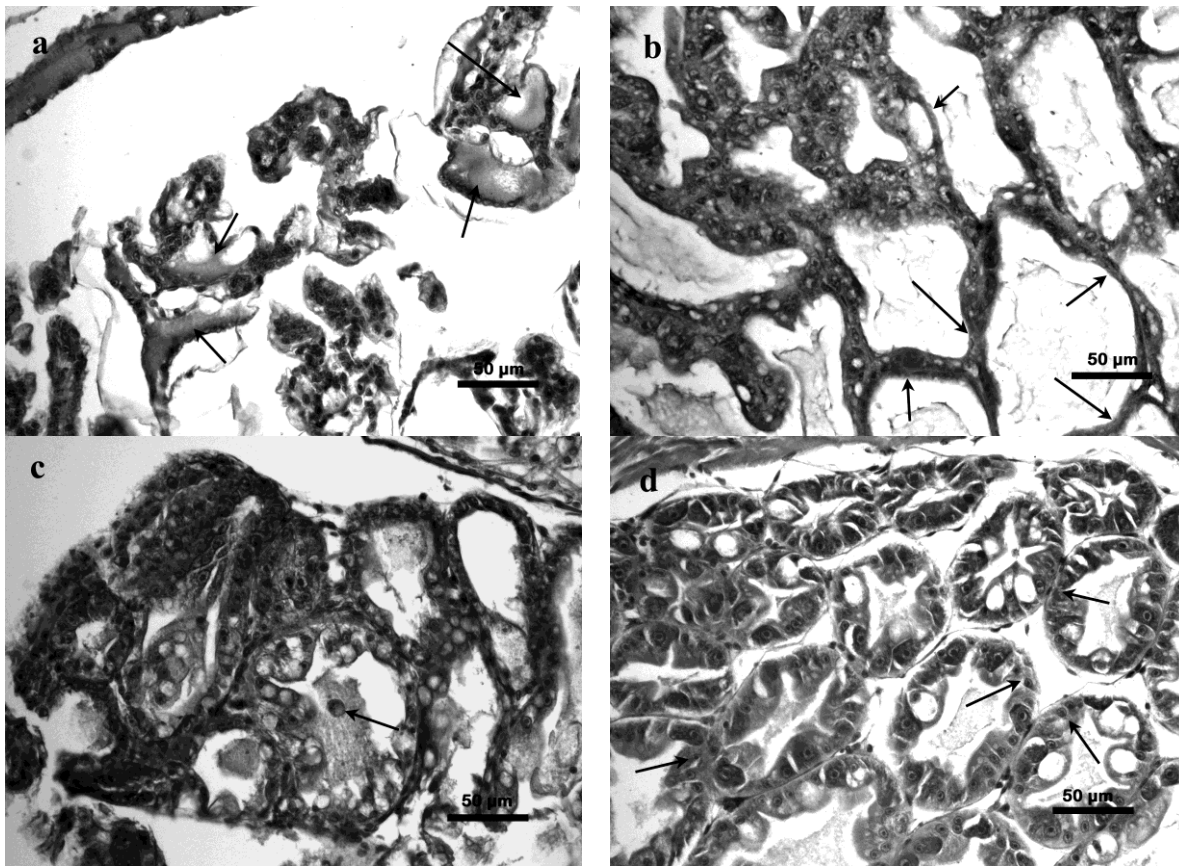


Figure 2. (a) $216 \mu\text{g L}^{-1}$ Cd + $640 \mu\text{g L}^{-1}$ Zn second week of exposure: Gill lacunae with moderate edemas (arrows). (b) $216 \mu\text{g L}^{-1}$ Cd + $640 \mu\text{g L}^{-1}$ Zn second week of exposure: R cells reduction in hepatopancreas (arrow). (c) $216 \mu\text{g L}^{-1}$ Cd + $640 \mu\text{g L}^{-1}$ Zn third week of exposure: sloughing of epithelial cells in hepatopancreas (arrow). (d) $216 \mu\text{g L}^{-1}$ Cd + $640 \mu\text{g L}^{-1}$ Zn fourth week of exposure: R cells reduction in hepatopancreas (arrow).

LC50-96h showed that the degree of damage was predominantly moderate, which coincides with the results obtained with a similar concentration ($200 \mu\text{g L}^{-1}$) by Wu, *et al.* (2008), while exposure during 21 days to a higher concentration ($400 \mu\text{g L}^{-1}$) resulted in highly vacuolized epithelial cells, cellular hypertrophy and tubular necrosis.

On the other hand, the moderate histological damage detected in the hepatopancreas of shrimps exposed during three to four weeks to between 320 and $640 \mu\text{g L}^{-1}$ of Zn does not differ from the slight to moderate damage (vacuolization) reported by Wu *et al.* (2008) in *L. vannamei* juveniles exposed for two-three weeks to $600 \mu\text{g L}^{-1}$ of Zn, although the degree of damage increased after longer exposures to the same concentration.

The damage caused by Cd could be due to reduced protein synthesis in the hepatocytes because of the cytotoxic effect of this metal (Wu and Chen, 2005), which is known to induce cell necrosis and accelerated apoptosis of cells of the immune system (Wang *et al.*, 2013), while in the case of the Zn-induced hepatopancreatic damage, the effect could be due to accelerated excretion through sloughing towards the lumen of metal-overloaded cells (Nuñez-Nogueira *et al.*, 2006).

The synergistic rather than the expected

antagonistic effect detected with the Cd + Zn mixture confirms that its toxicity cannot be predicted from the toxic effect of its single components, because their joint effect may be synergistic or antagonistic, depending on the species on which the mixture is tested, and even on the organ or tissue used for this test (Tkalec *et al.*, 2014).

The duration of exposure to sublethal concentrations of a xenobiotic is expected to increase its toxic effect (Newman and McCloskey, 1996). The lack of histopathologies after four weeks of exposure to single metals and to their mixture might be taken as an indication of a time-related weakening of the synergistic effect (Preston *et al.*, 2000), or of the capacity to recover a normal hepatopancreas structure even in the presence of metals, when the time of exposure is sufficiently long.

This capacity was observed after cessation of exposure by Chiodi-Boudet *et al.* (2015) in *Palaemonetes argentinus*, and the energetic demand of this process is likely to depend on the degree of histological damage. This was more evident in the case of the Cd + Zn mixture, which might explain the progressively slower growth and smaller sizes observed with increasing concentrations of this mixture.

Acknowledgments

Supported by PROFAPI 2013/065, PROMEP 103.5/13/9354 and CONACYT INFRA-2012-01-188029 grants. I. Priscilla Rosas helped with data processing.

References

- APHA. 1992. Standard methods for examination of water and wastewater. American Public Health Association. 17 edition, Washington DC.
- Barbieri, E. 2009. Effects of zinc and cadmium on oxygen consumption and ammonia excretion in pink shrimp (*Farfantepenaeus paulensis*, Pérez-Farfante, 1967, Crustacea). *Ecotoxicology*, 18: 312-318. doi 10.1007/s10646-008-0285-y
- Buikema, A.L., Niederleener R.R. and Cairns J.J. 1982. Biological monitoring part IV. Toxicity testing. *Water Research*, 16: 239-262.
- Chiodi-Boudet, L.N., Polizzi P., Romero M.B., Robles A., Marcovecchio J.E. and Gerpe M.S. 2015. Histopathological and biochemical evidence of hepatopancreatic toxicity caused by cadmium in white shrimp, *Palaemonetes argentinus*. *Ecotoxicology and Environmental Safety*, 113: 231-240. doi 10.1016/j.ecoenv.2014.11.019
- EPA. 2009. National recommended water quality criteria. Aquatic life criteria table. <http://water.epa.gov/scitech/swguidance/standards/criteria/current/upload/nrwqc-2009.pdf> (accessed September 12, 2015).
- Finney, D. 1971. Probit analysis, 3rd ed. Cambridge University Press. New York. 333 pp.
- Franco, A.R., Ferreira J.G. and Nobre A.M. 2006. Development of a growth model for penaeid shrimp. *Aquaculture*, 259: 268-277. doi 10.1016/j.aquaculture.2006.05.051
- Frías-Espéricueta, M.G., Voltolina D. and Osuna-López J.I. 2001. Acute toxicity of Cd, Hg and Pb to whiteleg shrimp *Penaeus vannamei* postlarvae. *Bulletin of Environmental Contamination & Toxicology*, 67: 580-586. doi 10.1007/s00128-001-0163-2
- Frías-Espéricueta, M.G., Voltolina D. and Osuna-López J.I. 2003. Acute toxicity of Cu, Zn, Fe and of the mixtures Cu-Zn and Fe-Mn to whiteleg shrimp *Litopenaeus vannamei* postlarvae. *Bulletin of Environmental Contamination & Toxicology*, 71: 68-74. doi 10.1007/s00128-003-0132-z
- Frías-Espéricueta, M.G., Castro-Longoria R., Barrón-Gallardo G.J., Osuna-López J.I., Abad-Rosales S.M., Páez-Osuna F. and Voltolina D. 2008. Histological changes and survival of *Litopenaeus vannamei* juveniles with different copper concentrations. *Aquaculture*, 278: 97-100. doi:10.1016/j.aquaculture.2008.03.008
- Frías-Espéricueta, M.G., Abad-Rosales S.M., Nevárez-Velázquez A.C., Osuna-López J.I., Páez-Osuna F., Lozano-Olvera R. and Voltolina D. 2008. Histological effects of a combination of heavy metals on Pacific white shrimp *Litopenaeus vannamei* juveniles. *Aquatic Toxicology*, 89: 152-157. doi:10.1016/j.aquatox.2008.06.010
- Frías-Espéricueta, M.G., Voltolina D., Osuna-López J.I. and Izaguirre-Fierro G. 2009. Toxicity of metals mixtures to the Pacific white shrimp *Litopenaeus vannamei* postlarvae. *Marine Environmental Research*, 68: 223-226. doi 10.1016/j.marenvres.2009.06.011
- Gunnarsson, J., Varjopuro R. and Eriksson L-Ö. 2000. Man and coastal areas towards a sustainable aquaculture: final report of the European workshop for a sustainable development of aquaculture. Service Scientifique et Technologique, Stockholm.
- Karlson, K. 1994. An investigation on the sensitivity to heavy metals of the tiger shrimp *Penaeus monodon*, a commercially important tropical shrimp. *Fisheries Development Series*, 82:29-33.
- Keating, J., Delaney M., Meehan-Meola D., Warren W., Alcivar A. and Alcivar-Warren A. 2007. Histological findings, cadmium bioaccumulation, and isolation of expressed sequence tags (ESTs) in cadmium-exposed, specific pathogen-free shrimp, *Litopenaeus vannamei* postlarvae. *Journal of Shellfish Research*, 26: 1225-1237. doi 10.2983/0730-8000(2007)26[1225:HFCBAI]2.0.CO;2
- Liao, I.C. and Hsieh C.J. 1988. Toxicity of heavy metals to *P. japonicus* I. Toxicities of copper, cadmium and zinc to *P. japonicus*. *Journal of the Fisheries Society of Taiwan*, 15: 69-78.
- López-Martínez, J., Rábago-Quiroz C., Nevárez-Martínez M.O., García-Juárez A.R., Rivera-Parra G.I. and Chávez-Villalba J. 2005. Growth, reproduction, and size at first maturity of blue shrimp, *Litopenaeus stylirostris* (Stimpson, 1874) along the east coast of the Gulf of California, Mexico. *Fisheries Research*, 71: 93-102. doi 10.1016/j.fishres.2004.06.004
- Negilski, D.S., Ahsanullah M. and Mobley M.C. 1981. Toxicity of zinc, cadmium and copper to the shrimp *Callinassa australiensis*. II. Effects of paired and triad combinations of metals. *Marine Biology*, 64: 305-309.
- Newman, M.C. and McCloskey J.T. 1996. Time-to-event analyses of ecotoxicity data. *Ecotoxicology*, 5: 187-196.
- Norwood, W.P., Borgmann U., Dixon D.G. and Wallace A. 2003. Effects of metal mixtures on aquatic biota: a review of observations and methods. *Human and Ecological Risk Assessment International Journal*, 9: 795-811. doi 10.1080/713610010
- Nuñez-Nogueira, G., Mouneyrac C., Amiard J.C. and Rainbow P.S. 2006. Subcellular distribution of zinc and cadmium in the hepatopancreas and gills of the decapod crustacean *Penaeus indicus*. *Marine Biology*, 150: 197-211. doi 10.1007/s00227-006-0350-0
- Nuñez-Nogueira, G., Fernández-Bringas L., Ordiano-Flores A., Gómez-Ponce A., Ponce de León-Hill C. and González-Farías F. 2012. Accumulation and regulation effects from the metal mixture of Zn, Pb, and Cd in the tropical shrimp *Penaeus vannamei*. *Biological Trace Element Research*, 150: 208-213. doi 10.1007/s12011-012-9500-z
- Odendaal, J.P. and Reinecke A.J. 2007. Quantitative assessment of effects of zinc on the histological structure of the hepatopancreas of terrestrial isopods. *Archives of Environmental Contamination & Toxicology*, 53: 259-364. doi 10.1007/s00244-006-0080-9
- Preston, S., Coad N., Townend J., Killham K. and Paton G.I. 2000. Biosensing the acute toxicity of metal interactions: are they additive, synergistic, or antagonistic? *Environmental Toxicological and Chemistry*, 19: 775-780. doi 10.1002/etc.5620190332
- Putranto, T.W.C., Andriani R., Munawwaroh A., Irawan B.

- and Soegianto A. 2014. Effect of cadmium on survival, osmoregulation and gill structure of the Sunda prawn, *Macrobrachium sintangense* (de Man), at different salinities. *Marine and Freshwater Behavior and Physiology*, 47: 349-360. doi 10.1080/10236244.2014.940703
- Santos, M.H.S., Troca da Cunha N. and Bianchini A. 2000. Effects of copper and zinc on growth, feeding and oxygen consumption of *Farfantepenaeus paulensis* postlarvae (Decapoda: Penaeidae). *Journal of Experimental Marine Biology and Ecology*, 247: 233-242. doi 10.1016/S0022-0981(00)00152-0
- Serafim, A. and Bebianno M.J. 2010. Effect of a polymetallic mixture on metal accumulation and metallothionein response in the clam *Ruditapes decussatus*. *Aquatic Toxicology*, 19: 370-378. doi 10.1016/j.aquatox.2010.05.016
- Sharma, S.S., Schat H., Vooijs R. and Van Heerwaarden L.M. 1999. Combination toxicology of copper, zinc, and cadmium in binary mixtures: Concentration-dependent antagonistic, nonadditive, and synergistic effects on root growth in *Silene vulgaris*. *Environmental Toxicology and Chemistry*, 18: 348-355. doi 10.1002/etc.5620180235
- Soegianto, A., Charmantier-Daures M., Trilles J.P. and Charmantier G. 1999. Impact of cadmium on the structure of gills and epipodites of the shrimp *Penaeus japonicus*. *Aquatic Living Resources*, 12: 57-70. doi 10.1016/S0990-7440(99)80015-1
- Tkalec, M., Štefanić P.P., Cvjetko P., Šikić S., Pavlica M. and Balen B. 2014. The effects of cadmium-zinc interactions on biochemical responses in tobacco seedlings and adult plants. *Plos One*, 9: e87582. doi 10.1371/journal.pone.0087582
- Usman, N., Irawan B. and Soegianto A. 2013. Effect of lead on survival, osmoregulation, and histological changes in gills of the white shrimp, *Litopenaeus vannamei*, Boone, 1931. *Journal of the World Aquaculture Society*, 44: 547-556. doi 10.1111/jwas.12054
- Vanegas, C., Espina S., Botello A.V. and Villanueva S. 1997. Acute toxicity and synergism of cadmium and zinc in white shrimp, *Penaeus setiferus*, juveniles. *Bulletin of Environmental Contamination & Toxicology*, 58: 87-92. doi 10.1007/s001289900304
- Wang, J., Zhang P., Shen Q., Wang Q., Liu D., Li J. and Wang L. 2013. The effects of cadmium exposure on the oxidative state and cell death in the gill of freshwater crab *Sinopotamon henanense*. *Plos One*, 8: e64020. doi 10.1371/journal.pone.0064020
- Wu, J.P. and Chen H.C. 2004. Effects of cadmium and zinc on oxygen consumption, ammonia excretion, and osmoregulation of the white shrimp (*Litopenaeus vannamei*). *Chemosphere*, 57: 1591-1598. doi 10.1016/j.chemosphere.2004.07.033
- Wu, J.P. and Chen H.C. 2005. Effects of cadmium and zinc on the growth, food consumption, and nutritional conditions of the white shrimp, *Litopenaeus vannamei* (Boone). *Bulletin of Environmental Contamination & Toxicology*, 74: 234-241. doi 10.1007/s00128-004-0575-x
- Wu, J.P., Chen H.C. and Huang D.J. 2008. Histopathological and biochemical evidence of the hepatopancreatic toxicity caused by cadmium and zinc in the white shrimp, *Litopenaeus vannamei*. *Chemosphere*, 73: 1019-1026. doi 10.1016/j.chemosphere.2008.08.019
- Zar, J.H. 2009. *Biostatistical Analysis*. Prentice Hall, Upper Saddle River, 960 pp.
- Zodrow, J.M., Stegeman J.J. and Tanguay R.L. 2004. Histological analysis of acute toxicity of 2, 3, 7, 8-tetrachlorodibenzo-*p*-dioxin (TCDD) in zebra fish. *Aquatic Toxicology*, 66: 25-38. doi 10.1016/j.aquatox.2003.07.002