



## Effects of Humic Acid on Liver and Kidney Toxicity Induced by Cadmium in Brown Trout (*Salmo trutta fario*, L)

Ahmet Topal<sup>1,\*</sup>, Gonca Alak<sup>2</sup>, Muhammed Atamanalp<sup>3</sup>, Ertan Oruç<sup>4</sup>, Saltuk Buğrahan Ceyhan<sup>3</sup>, Arzu Uçar<sup>3</sup>, Harun Arslan<sup>3</sup>, Fikret Çelebi<sup>5</sup>, Yavuz Selim Sağlam<sup>4</sup>

<sup>1</sup> Ataturk University, Faculty of Fisheries, Department of Basic Sciences, TR-25240 Erzurum, Turkey.

<sup>2</sup> Department of Agricultural Biotechnology, Faculty of Agriculture, Ataturk University, TR-25240 Erzurum, Turkey.

<sup>3</sup> Department of Aquaculture, Faculty of Fisheries, Ataturk University, TR-25240 Erzurum, Turkey.

<sup>4</sup> Department of Pathology, Faculty of Veterinary, Ataturk University, TR-25240 Erzurum, Turkey.

<sup>5</sup> Department of Physiology, Faculty of Veterinary, Ataturk University, TR-25240 Erzurum, Turkey.

\* Corresponding Author: Tel. +90.442 2312434; Fax: +90.442 2361128;  
E-mail: drahmertopal@hotmail.com

Received 16 July 2012  
Accepted 6 October 2013

### Abstract

This study was conducted to determine the histopathological and biochemical effects of humic acid on cadmium stress in liver and kidney tissues of *Salmo trutta fario*, L. The fish were treated in four groups as follows and were exposed to chemicals for 7 days: control (C), cadmium (2 ppm) (Cd), humic acid (5 ppm) (HA) and humic acid + cadmium (Cd + HA). At the end of the experimental period, liver and kidney samples were taken from all fish for histopathological examination and determination of antioxidant enzyme (glutathione peroxidase, superoxide dismutase) and malondialdehyde (MDA) levels. Activity of GPx and SOD in the tissues of fish exposed to the stress of Cd was significantly lower than the control groups ( $P < 0.05$ ). MDA level increased ( $P < 0.05$ ) in cadmium exposed groups, whereas fish receiving cadmium with humic acid returned to normal MDA levels in the liver. The cadmium-induced histopathological alterations were also decreased with humic acid. These results suggest that humic acid may mediate cadmium toxicity.

**Keywords:** Heavy metal, antioxidant, histopathology, *Salmo trutta fario*, humic acid.

### Kahverengi Alabalıkta Kadmiyum ile Oluşturulmuş Karaciğer ve Böbrek Toksikitesi Üzerine Humik Asitin Etkileri

#### Özet

Bu çalışma kahverengi alabalığın karaciğer ve böbrek dokularında, kadmiyum stresi üzerine humik asitin histopatolojik ve biyokimyasal etkilerini tespit etmek amacıyla yapıldı. Balıklar aşağıdaki gibi dört gruba ayrıldı ve yedi gün kimyasallara maruz bırakıldı: kontrol (C), kadmiyum (2 ppm) (Cd), humik asit (5 ppm) (HA) ve humik asit + kadmiyum (Cd+HA). Deneysel periyodun sonunda, bütün balıklardan histopatolojik inceleme ve antioksidan enzim tespiti (glutasyon peroksidaz, süperoksit dismutaz) ve malondialdehit (MDA) düzeyleri için karaciğer ve böbrek örnekleri alındı. Kadmiyum stresine maruz kalan balıkların dokularında

GPx ve SOD aktiviteleri kontrol grubundan daha düşüktü ( $P < 0.05$ ). Kadmiyuma maruz kalan gruplarda MDA düzeyleri arttı fakat humik asitle kadmiyum alan balıkların karaciğerinde MDA düzeyleri normale döndü ( $P < 0.05$ ). Ayrıca kadmiyum ile indüklenmiş histopatolojik değişiklikler humik asitle azaldı. Bu sonuçlar, humik asitin kadmiyum toksisitesini önleyebileceğini destekliyor.

**Anahtar Kelimeler:** Ağır metal, antioksidan, histopatoloji, *Salmo trutta fario*, humik asit.

#### Introduction

Heavy metals enter the aquatic environment from farms and urban and industrial production sites and cause long-term ecotoxicological effects (Ates *et al.*, 2008). Heavy metal contamination in the terrestrial as well as the aquatic environment is a worldwide problem of increasing magnitude. Heavy metals can affect aquatic organisms through water, sediment or

the food chain (Remyła *et al.*, 2008). Cadmium is considered as one of the most toxic heavy metals. It is a nonessential element to all living organisms. (Randi *et al.*, 1996; Besirovic *et al.*, 2010). Cadmium has been reported to exert deleterious effects in terms of nephrotoxic, genotoxic, immunotoxic (ATSDR, 1999). Cadmium in water is taken in through respiration and digestion and then passes through other organs. The liver plays a major role in

detoxification through inducing the expression of the metal binding molecule metallothionein (Kayhan, 2006). It accumulates mainly in vital organs such as the liver and kidney where it has damaging effects (Sinha *et al.*, 2007). Accumulation of cadmium in living organisms is a major ecological concern especially because of its ability to accumulate very quickly. Cadmium can cause a number of structural and pathomorphological changes in various organs of fish. The highest cadmium levels were detected in the kidneys and liver of fish (Thophon *et al.*, 2003). A number of investigations have suggested that cadmium may exert immunosuppressive effects of cadmium exposure in both fish and mammals (Kumar, 2010). Organisms have evolved a variety of mechanisms to protect themselves from the toxic effects of essential and nonessential heavy metals that cause oxidative stress (Basha and Rani, 2003). Cellular oxidative stress occurs when pro-oxidant forces overwhelm antioxidant defences (Li *et al.*, 2011). Some important antioxidant enzymes are superoxide dismutase (SOD), catalase (CAT), glutathione peroxidase (GPx) and glutathione reductase (GR) (Wilhelm, 1996; Li *et al.*, 2011). ROS, which cause tissue damage, are decreased by antioxidant enzymes (Halliwell *et al.*, 1995).

Humic substances are structurally complex large to macromolecules which occur in soils and natural waters as a consequence of the breakdown of plant and animal residues by microbial activity (Jones, 1998). Aquatic humic substances are a category of the most widely distributed organic matters that constitute 30–50% of dissolved organic matter (DOM) in natural aquatic systems (Lu *et al.*, 2009). Humic acid is ubiquitous in the environment and has been found to influence physiological functions of aquatic organisms (Andersson *et al.*, 2010). Certain studies show that it has growth related effect as well as health protection capacity by changing some physiology and developing immunity in different species of animals (Islam *et al.*, 2005).

The aim of the present study is to determine the protective effect of humic acid against cadmium stress in the liver and kidney tissues of brown trout. Toxicity was assessed histopathologically. The activities of glutathione peroxidase (GPx), superoxide dismutase (SOD) and the alterations in malondialdehyde (MDA) levels are determined.

## Materials and Methods

### Fish Husbandry and Maintenance

The cadmium chloride used in this study was of analytically reagent grade and was purchased from Sigma Chemical Co. (St. Louis, MO) and humic acid obtained from Farmavet Medicine. These solid substances were dissolved in water. Brown trout, *Salmo trutta fario*, L. were obtained from Atatürk University, Faculty of Fisheries, and the Inland water

fish Breeding and Research Center. The research was arranged in the fish toxicology laboratory of the same faculty. The experiments were performed according to the approved ethical rules. Fish were fed for 15 days in a stock pond to provide their acclimatization to the environmental conditions. After the adaptation period, ten fish were placed in each 400 L volume water fiberglass tanks. The tested fish had an average  $203.31 \pm 8.09$  g weight and  $22.21 \pm 0.49$  cm length. The physico-chemical properties of the tank water were: temperature (10–12°C); pH (7.4–8.0); dissolved oxygen ( $7.52 \pm 0.50$  ppm); water hardness ( $164.1 \pm 4.17$  ppm) ( $\text{CaCO}_3$ ). The concentrations of the Cd and HA in the stock solutions were that the exposure concentrations (ppm) was Cd 2ppm, while HA was 5ppm (Talas *et al.*, 2008; Kamunde and MacPhail, 2011). Fish were divided into four groups. There was one tank for each group. Each groups contained ten fish. The fish in group I were the control. The fish in group II were given a single dose of 2 ppm concentration of cadmium chloride ( $\text{CdCl}_2$ ). This dose was selected because it had been previously reported to induce toxicity in rainbow trout (Talas *et al.*, 2008). The fish in group III were exposed to a single dose of 5 ppm concentration of humic acid. The fish in group IV were exposed to a mixture dose of 2 ppm cadmium chloride and 5 ppm humic acid. Chemicals were administered by adding to water for 7 days.

### Biochemical Assays

Glutathione peroxidase (GPx), superoxide dismutase (SOD), and malondialdehyde (MDA) levels in brown trout tissues analyzed according to Alak *et al.* (2013). Extracts from each tissue were prepared from each individual in according to Wiegand *et al.* (2001) with slight modifications. Sample were homogenized by  $\text{KH}_2\text{PO}_4$  (30 mM, pH=7.3) buffer. Homogenates were then centrifuged at 13000 rpm, 2 hours at 4°C. Antioxidant enzyme activities–SOD, GPx and MDA concentration were determined on the supernatants. All results were referred to the protein content in the samples. The MDA levels of fish tissues were estimated according to Gülçin *et al.*, 2009. 200 µl hemolysate, 800 µl phosphate buffer (50 mM, pH 7.4), 25µl BHT and 500µl of 30% TCA (trichloroacetic acid) were added mixed fast and incubated at -20°C for 2 hours and then centrifuged at 2000 rpm for 15 min. 1.0 ml supernatant was separated. Afterwards 75 µl EDTA- $\text{Na}_2\text{H}_2\text{O}$ , 250 µl TBA (thiobarbituric acid) were added to each sample and the control. Then samples were placed in a boiling water bath for 15 min, cooled to room temperature, and measured at 532 nm. Total thiobarbituric acid-reactive materials are expressed as MDA, using a molar extinction coefficient for MDA of  $1.56 \times 10^5 \text{ cm}^{-1}$ . The protein content of each homogenate was measured according to Bradford (1976) with Coomassie Brilliant Blue G-250 using bovine serum albumin as a standard.

## Histopathology Assays

Tissue samples from livers and kidneys were collected and fixed in 10% buffered neutral formalin solution. After the routine alcohol-xylol process, tissue samples were embedded in paraffin and sectioned in 5µm. All sections were stained with hematoxylin-eosine (H-E) and evaluated by high-power light microscopic examination (Olympus BX52 with DP72 camera system). All histopathological alterations were estimated with an image processing system (Olympus, DP2-BSW). For each specimen, tissue changes were examined in 10 randomly selected areas of approximately X40 objective. The scores were derived semi-quantitatively using light microscopy on the preparations and were reported as follows in Table 1: none: -, mild: +, moderate: ++, and severe: +++.

## Statistical Analyses

All values were expressed as mean±SD. Statistical analysis of data was performed using a one-way analysis of variance (ANOVA) and Duncan test and analysed using SPSS version 10.0 (SPSSInc., Chicago, IL, USA) software. A value of P<0.05 was

considered statistically significant.

## Results

### Biochemical Results

Cd caused a significant decrease in GPx and SOD levels in brown trout's liver and kidney compared with the control group (P<0.05)(Table 2-3). There were statistically significant increases in MDA levels in liver and kidney of fish exposed to Cd (P<0.05). HA treatment with Cd did not produce a significant increase in the level of GPx in the liver and kidney compared with the Cd group. HA treatments with Cd produced improve SOD and MDA levels in the liver compared with the Cd group (Table 2) (P<0.05). Also it was observed that there were no significant (P>0.05) convergences in comparison to the control group values for MDA activity in kidney tissue of brown trout (Table 3).

### Histopathological Results

The histopathological views of the control group were normal (Figure 1-a) (Figure 2-a). Similarly, no

**Table 1.** The intensity and severity of histopathological changes in liver and kidney tissues

Histopathologic lesion	Control group	HA group	Cd group	Cd+HA group
<b>Liver</b>				
Hyperemia	-	-	+	-
Cytoplasmic vacuoles	-	-	++	-
Increase in Kupffer cells	-	-	++	+
Picnotic nuclei	-	-	++	+
<b>Kidney</b>				
Hyperemia	-	-	+	-
Hyaline material in tubuli	-	-	++	+
Picnotic nuclei	-	-	++	-

**Table 2.** Changes in the liver tissue (GPx, SOD activity and MDA levels) with humic acid administration on fish exposed to heavy metal (Cd)

	GPx (µmol/mg prot.)	SOD (U/mg prot.)	MDA (nmol/mg prot.)
Control	2.73±1.40 <sup>a</sup>	0.33±0.08 <sup>b</sup>	0.17±0.02 <sup>b</sup>
HA	2.12±0.89 <sup>a</sup>	0.40±0.25 <sup>b</sup>	0.12±0.02 <sup>b</sup>
Cd	1.06±0.68 <sup>b</sup>	0.16±0.03 <sup>c</sup>	0.35±0.14 <sup>a</sup>
Cd+HA	1.05±1.00 <sup>b</sup>	0.44±0.14 <sup>b</sup>	0.15±0.06 <sup>b</sup>

All data points are the average of n = 8 ± SD. Different superscript letters indicate statistically significant differences (P< 0.05)

**Table 3.** Changes in the kidney tissue (GPx, SOD activity and MDA levels) with humic acid administration on fish exposed to heavy metal (Cd)

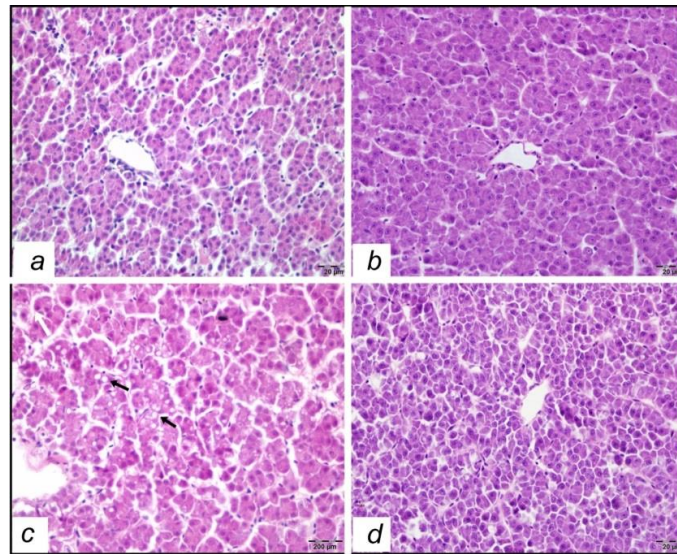
	GPx (µmol/mg prot.)	SOD (U/mg prot.)	MDA (nmol/mg prot.)
Control	1.57±0.98 <sup>a</sup>	0.25±0.06 <sup>b</sup>	0.61±0.40 <sup>b</sup>
HA	0.99±0.57 <sup>ab</sup>	0.31±0.27 <sup>b</sup>	0.40±0.21 <sup>b</sup>
Cd	0.95±0.43 <sup>ab</sup>	0.11±0.06 <sup>c</sup>	1.07±0.07 <sup>a</sup>
Cd+HA	0.95±0.70 <sup>ab</sup>	0.28±0.10 <sup>b</sup>	1.08±0.21 <sup>a</sup>

All data points are the average of n = 8 ± SD. Different superscript letters indicate statistically significant differences (P< 0.05)

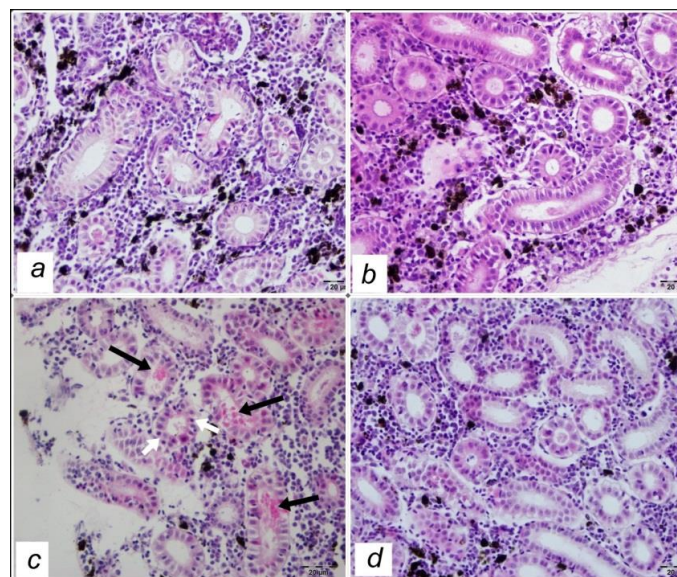
histopathological alterations were observed in the HA group (Figure 1-b and 2-b). Prominent changes were observed in experimental Cd group. Cytoplasmic vacuole formations and an increase in kupffer cells and picnotic nuclei were observed in this group (Figure 1-c). In kidney sections, hyaline material in some tubuli was prominent (Figure 2-c). Besides, some tubular epithelium contains picnotic nuclei. This non-specific changes in both liver and kidney sections were observed in mild degree in Cd+HA group (Figure 1-d and Figure 2-d). The intensity and severity of histopathological changes were displayed in Table 1.

## Discussion

Heavy metals from anthropogenic sources have been recognized as important contaminants in aquatic ecosystems (Dabas *et al.*, 2011). In polluted areas, exposure of fish to heavy metal leads to interactions between these chemicals and biological systems, which give rise to biochemical disturbances (Talas *et al.*, 2008). Biochemical constituents, like lipid peroxidation and antioxidant enzymes, are the potential biomarkers of pollutants exposure in different organisms (Livingstone, 2003; Regoli *et al.*, 2004). Antioxidant enzymes such as glutathione



**Figure 1.** Liver. Normal histologic appearance of liver tissue in the control (a) and humic acid (b) groups. Moderate vacuole formations (black arrows) and picnotic nuclei in the cadmium groups (c) (white arrow- left top). Decrease in the severity of Cd damage in the Cd+HA group (d).



**Figure 2.** Kidney. Normal histologic appearance of kidney tissue in the control (a) and humic acid (b) groups. Hyaline content (black arrows) and picnotic nuclei in the cadmium group (c) (white arrow). Decrease in the severity of Cd damage in the Cd+HA group (d).

peroxidase and superoxide dismutase that prevent oxidative stress (Stajn *et al.*, 1997; Ognjanovic *et al.*, 2008). In particular, the level of antioxidant enzyme is a satisfactory indicator for the impacts of pollutants like heavy metals. Heavy metal damage is an important factor in many pathological and toxicological processes (Ates *et al.*, 2008). Cadmium exposure also reportedly affects antioxidant defenses in fish. In this sense, it had been shown that Cd can compete with essential metals in protein-binding sites, triggering a release of  $Fe^{2+}$  and  $Cu^{2+}$  ions and increased generation of ROS (Pruski and Dixon, 2002).

In the present study, the activity of antioxidant GPx and SOD in the liver and kidney in the cadmium group was significantly decreased (Table 2-3) compared with their levels of controls ( $P < 0.05$ ). Our findings are similar to the results of Talas *et al.* (Talas *et al.*, 2008). These results clearly indicated that SOD and GPx may play a role in the suppression of oxygen free radical formation in liver and kidney tissues. Also, this result may be connected to the Cd-induced increase in free radical generation or a decrease in amounts of protecting enzymes against lipid peroxidation. The decrease in SOD and GPx activity in the liver of cadmium-treated samples may indirectly cause oxidative DNA damage or mitochondrial damage in cells (Karadeniz *et al.*, 2009). In other studies, the superoxide radicals by themselves or after their transformation to  $H_2O_2$  cause an oxidation of the cysteine in the enzyme and decrease SOD activity (Oruc and Uner, 2000). Decreases in SOD activity level were found in erythrocytes of *Cyprinus carpio* exposed to MS 222 which is used for anesthesia, sedation, or euthanasia of fish (Bartowiak *et al.*, 1981). Also, the decreased activity of GPx may be the result of  $O_2^-$  production (Oruc and Uner, 2000). We may explain that Cd may cause modifications in the enzyme structures by interacting with the enzyme cofactors or possible inductions of stress proteins. It had been reported that cadmium damaged mitochondrial enzyme activities by causing defects in cells and tissues (Lacroix and Hontela, 2004). Also, cadmium produces an inhibitory effect on mitochondria electron transport, and as a result, the respiratory chain becomes highly reduced and the electrons are transferred directly to available oxygen, leading to an enhancement in the ROS formation, which causes peroxidative damage in the liver, kidney and gills (Dabas *et al.*, 2011). Fish exposed to cadmium with humic acid returned to normal SOD levels in liver and kidney. The treatment with HA ameliorated the Cd-induced liver and kidney damages due to free radical production. These results suggested that humic acid may have a supporting effect on the antioxidant system.

The lipid peroxidation, as induced by heavy metal pollution in aquatic organisms, is expressed by malondialdehyde (MDA) formation (Draper *et al.*, 1993). Therefore, it has been used as a biomarker of

pollution (Sayeed *et al.*, 2003). The levels of MDA in the liver and kidney were significantly increased (Table 2-3) in cadmium group ( $P < 0.05$ ). Although fish cadmium + humic acid group returned to normal MDA levels in the liver. Therefore, it may be suggested that the protective effect of humic acid against cadmium-induced oxidative stress could be either direct by inhibiting lipid peroxidation or scavenging free radicals or indirect through the enhancement of the activity of superoxide dismutase, the enzymatic free radicals scavengers in the cells.

The livers of the control group showed normal histological features, but the Cd-treated group revealed vacuole formations, increase of kupffer cell and picnotic nuclei (Figure 1c). Kumar (2010) reported that cadmium accumulates in liver of fish in high concentrations (Kumar, 2010) and it also induces various pathological alterations in liver tissues including engorgement of blood vessels, congestion, vacuolar degeneration of hepatocytes and fatty changes in the hepatocytes (Dangre *et al.*, 2010; Kumar, 2010). Kidney is the principle target organ of cadmium toxicity and chronic cadmium exposure in almost all animal species is characterized by varying degree of renal damage (Romeo *et al.*, 2000; Kumar *et al.*, 2009). Histopathological results of the present study showed that Cd caused a significant increase in histopathological changes such as hyperemia, hyaline material in tubuli and picnotic nuclei in the kidney tissue (Figure 2c). Additionally, the treatment with humic acid led to decrease in the histopathological changes (Figure 2d). The protective action, combined with antioxidant activity, has a synergistic effect in preventing the process of initiation and progress of liver and kidney damage.

These results may provide direct evidence for the preservation role of HA with physiological nonenzymatic antioxidant properties on the antioxidative defence system against toxic metals as Cd. HA may contribute to the antioxidative defence system. Biochemical and histopathological parameters can be accepted as sensitive biomarkers of the aquatic environment before the detrimental effects occur for aquatic species.

## Acknowledgement

The authors would like to thank Ataturk University for financial support of the study (Project no: 2011/426).

## References

- Alak, G., Atamanalp, M., Topal, A., Arslan, H., Kocaman, E.M. and Oruç, E. 2013. Effect of sub-lethal lead toxicity on the histopathological and antioxidant enzyme activity of rainbow trout (*Oncorhynchus mykiss*). Fresenius Environmental Bulletin, 22: 733-738. "
- Andersson, C., Abrahamson, A., Brunström, B. and Örborg, J. 2010. Impact of humic substances on EROD

- activity in gill and liver of three-spined sticklebacks (*Gasterosteus aculeatus*). *Chemosphere*, 81: 156–160. doi: 10.1016/j.chemosphere.2010.06.073
- Ates, B., Orun, I., Talas, Z.S., Durmaz, G. and Yilmaz, I. 2008. Effects of sodium selenite on some biochemical and hematological parameters of rainbow trout (*Oncorhynchus mykiss* Walbaum, 1792) exposed to Pb<sup>2+</sup> and Cu<sup>2+</sup>. *Fish Physiology and Biochemistry*, 34: 53–59. doi: 10.1007/s10695-007-9146-5
- ATSDR, 1999. Toxicol. Profile of Cadmium. Agency for Toxic Substances and Drug Registrar, Atlanta, GA. US Deptt. Of Health and Human Services.
- Bartowiak, A., Grzelinska, E., Varga, I.S. and Leyko, W. 1981. Studies on superoxide dismutase from cod (*Gadus morhua*) liver. *The International Journal of Biochemistry & Cell Biology*, 13: 1039–1042. doi:10.1016/0020-711X(81)90011-2
- Basha, P.S. and Rani, A.U. 2003. Cadmium-induced antioxidant defense mechanism in freshwater teleost *Oreochromis mossambicus* (Tilapia). *Ecotoxicology and Environmental Safety*, 56(2): 218–21. doi:10.1016/S0147-6513(03)00028-9
- Besirovic, H., Alic, A., Prasovic, S. and Drommer, W. 2010. Histopathological effects of chronic exposure to cadmium and zinc on kidneys and gills of brown trout (*Salmo trutta m. fario*). *Turkish Journal of Fisheries and Aquatic Sciences*, 10: 255–262. doi: 10.4194/trjfas.2010.0214
- Bradford, M.M. 1976. Rapid and sensitive method for the quantitation of microgram quantities of protein utilizing the principle of protein-dye binding. *Analytical Biochemistry*, 72: 248–254. doi: 10.1016/0003-2697(76)90527-3
- Dabas, A., Nagpure, N. S., Kumar, R., Kushwaha, B., Kumar, P. and Lakra, W.S. 2012. Assessment of tissue-specific effect of cadmium on antioxidant defense system and lipid peroxidation in freshwater murrel, *Channa punctatus*. *Fish Physiology and Biochemistry*, 38: 469–82. doi: 10.1007/s10695-011-9527-7
- Dangre, A.J., Manning, S. and Brouwer, M. 2010. Effects of cadmium on hypoxia-induced expression of hemoglobin and erythropoietin in larval sheepshead minnow, *Cyprinodon variegates*. *Aquatic Toxicology*, 99: 168–175. doi: 10.1016/j.aquatox.2010.04.015
- Draper, H.H., Squires, E.J., Mahmooch, H., Wu, J., Agarwal, S. and Handley, M. 1993. A comparative evaluation of thiobarbituric acid methods for the determination of malondialdehyde in biological materials. *Free Radical Biology and Medicine*, 15: 353–363. doi: 10.1016/0891-5849(93)90035-S
- Gülçin, İ., Beydemir, Ş., Hisar, O., Köksal, E. and Reiter, R.J. 2009. Melatonin administration increases antioxidant enzymes activities and reduces lipid peroxidation in the rainbow trout (*Oncorhynchus mykiss*, Walbaum) erythrocytes. *Turkish Journal of Veterinari Animal and Sciences*, 33: 241–245. doi:10.3906/vet-0803-1
- Halliwell, B., Aeschbach, R., Loliger, J. and Aruoma, O.I. 1995. The characterization of antioxidants. *Food and Chemical Toxicology*, 33: 601–617. doi:10.1016/0278-6915(95)00024-V
- Jones, M. N. and Bryan, N.D. 1998. Colloidal properties of humic substances. *Adv. Colloid and Interface Science*, 78: 1–48. doi: 10.1016/S0001-8686(98)00058-X
- Islam, K.M.S., Schuhmacher, A. and Gropp, J.M. 2005. Humic Acid Substances in Animal Agriculture. *Pakistan Journal of Nutrition*, 4: 126–134. doi: 10.3923/pjn.2005.126.134
- Kamunde, C. and MacPhail, R. 2011. Effect of humic acid during concurrent chronic waterborne exposure of rainbow trout (*Oncorhynchus mykiss*) to copper, cadmium and zinc. *Ecotoxicology and Environmental Safety*, 74: 259–269. D doi: 10.1016/j.ecoenv.2010.10.007
- Karadeniz, A., Cemek, M. and Simsek, N. 2009. The effects of Panax ginseng and Spirulina platensis on hepatotoxicity induced by cadmium in rats. *Ecotoxicology and Environmental Safety*, 72: 231–235. doi: 10.1016/j.ecoenv.2008.02.021
- Kayhan, F.E. 2006. Bioaccumulation and toxicity of cadmium in the water products. *Journal of Fisheries Aquatic Science*, 23: 215–220.
- Kumar, P., Prasad, Y., Patra, A.K., Ranjan, R., Patra, R.C., Swarup, D. and Singh, S.P. 2009. Ascorbic acid, garlic extract and taurine alleviate cadmium-induced oxidative stress in freshwater catfish (*Clarias batrachus*). *The Science Total Environment*, 407: 5024–5030. doi: 10.1016/j.scitotenv.2009.05.030
- Kumar, P. and Singh, A. 2010. Cadmium toxicity in fish: An overview. *GERF Bulletin of Biosciences* December 1(1): 41–47. doi: 10.1016/j.aquatox.2003.11.010
- Lacroix, A. and Hontela, A. 2004. A comparative assessment of the adrenotoxic effects of cadmium in two teleost species, rainbow trout, *Oncorhynchus mykiss*, and yellow perch, *Perca flavescens*. *Aquatic Toxicology*, 67: 13–21. doi: 10.1016/j.aquatox.2003.11.010
- Li, ZH., Zlabek, V., Velisek, J., Grabic, R., Machova, J., Kolarova, J., Li, P. and Randak, T. 2011. Acute toxicity of carbamazepine to juvenile rainbow trout (*Oncorhynchus mykiss*): Effects on antioxidant responses, hematological parameters and hepatic EROD. *Ecotoxicology and Environmental Safety*, 74: 319–327. doi: 10.1016/j.ecoenv.2010.09.008
- Livingstone, D.R. 2003. Oxidative stress in aquatic organisms in relation to pollution and aquaculture. *Revue Medecine Veterinaire*, 154: 427–430.
- Lu, J.J., Li, Y., Yan, X.M., Shi, B.Y., Wang, D.S. and Tang, H. X. 2009. Sorption of atrazine onto humic acids (HAs) coated nanoparticles. *Colloids and Surfaces A: Physicochemical and Engineering Aspects*, 347: 90–96. doi: 10.1016/j.colsurfa.2008.12.032
- Ognjanovic, B.I., Markovic, S.D., Pavlovic, S.Z., Zikic, R.V., Stajn, A.S. and Saicic, Z.S. 2008. Effect of chronic cadmium exposure on antioxidant defense system in some tissues of rats: protective effect of selenium. *Physiological Research*, 57: 403–411.
- Oruc, E. O. and Uner, N. 2000. Combined effects of 2,4-D and azinphosmethyl on antioxidant enzymes and lipid peroxidation in liver of *Oreochromis niloticus*. *Comparative Biochemistry and Physiology*, 127: 291–296. doi: 10.1016/S0742-8413(00)00159-6
- Pruski, A.M. and Dixon, D.R. 2002. Effects of cadmium on nuclear integrity and DNA repair efficiency in the gill cells of *Mytilus edulis* L. *Aquatic Toxicology*, 57: 127–137. doi: 10.1016/S0166-445X(01)00192-8
- Randi, A.S., Monserrat, J.M., Rodriguez, E.M. and Romano, L.A. 1996. Histopathological effects of cadmium on the gills of the freshwater fish, *Macropsobrycon uruguayanae* Eigenmann 1915 (Pisces, Atherinidae). *Journal of Fish Diseases*, 19:

- 311–322. doi: 10.1046/j.1365-2761.1996.d01-82.x
- Regoli, F., Frenzilli, G., Bochetti, R., Annarumma, F., Scarcelli, V., Fattorini, D. and Nigro, N. 2004. Time-course variations of oxyradical metabolism, DNA integrity and lysosomal stability in mussels, *Mytilus galloprovincialis*, during a field translocation experiment. *Aquatic Toxicology*, 68: 167–178. doi: 10.1016/j.aquatox.2004.03.011
- Remyła, S.R., Ramesh, M., Sajwan, K.S. and Kumar, K.S. 2008. Influence of zinc on cadmium induced haematological and biochemical responses in a freshwater teleost fish *Catla catla*. *Fish Physiology and Biochemistry*, 34: 169–174. doi: 10.1007/s10695-007-9157-2
- Sayeed, I., Parvez, S., Pandey, S., Bin-Hafeez B., Haque, R. and Raisuddin, S. 2003. Oxidative stress biomarkers of exposure to deltamethrin in freshwater fish, *Channa punctatus* Bloch. *Ecotoxicology and Environmental Safety*, 56: 295–301. doi: 10.1016/S0147-6513(03)00009-5
- Sinha, M., Manna, P.C. and Sil, P.C. 2007. Attenuation of cadmium chloride induced cytotoxicity in murine hepatocytes by a protein isolated from the leaves of the herb *Cajanus indicus* L. *Archives of Toxicology*, 81: 397–406. doi: 10.1007/s00204-007-0176-7
- Stajn, A., Zikic, R.V., Ognjanovic, B., Saicic, Z.S., Pavlovic, S.Z., Kostic, M.M. and Petrovic, V.M. 1997. Effect of cadmium and selenium on the antioxidant defense system in rat kidneys. *Comparative Biochemistry and Physiology Part C, Pharmacology, Toxicology & Endocrinology*, 117: 167–172. doi: 10.1016/S0742-8413(97)00063-7
- Talas, Z.S., Orun, I., Ozdemir, I., Erdogan, K., Alkan, A. and Yilmaz, I. 2008. Antioxidative role of selenium against the toxic effect of heavy metals ( $\text{Cd}^{+2}$ ,  $\text{Cr}^{+3}$ ) on liver of rainbow trout (*Oncorhynchus mykiss* Walbaum 1792). *Fish Physiology and Biochemistry*, 34: 217–222. doi: 10.1007/s10695-007-9179-9
- Thophon, S., Kruatrachue, M., Upatham, E.S., Pokethitiyook, P., Sahaphong, S. and Jaritkuan, S. 2003. Histopathological alterations of white seabass, *Lates calcalifer*, in acute and subchronic cadmium exposure. *Environmental Pollution*, 121: 307–320.
- Wiegand, C., Krause, E., Steinberg, C., Pflugmacher, S. 2001. Toxicokinetics of atrazine in embryos of the zebrafish (*Danio rerio*). *Ecotoxicology and Environmental Safety*, 49: 199–205. doi: 10.1006/eesa.2001.2073
- Wilhelm, D. 1996. Fish antioxidant defenses—a comparative approach. *Brazilian Journal of Medical and Biological Research*, 29: 1735–1742.