



Effects of Fish Oil Replacement with Vegetable Oils in Rainbow Trout (*Oncorhynchus mykiss*) Fingerlings Diet on Growth Performance and Foregut Histology

Rasoul Shahrooz^{1,*}, Naser Agh², Nasim Jafari³, Ali Kalantari¹, Reza Jalili³, Ali Karimi¹

¹ Urmia University, Faculty of Veterinary Medicine, Department of Histology and Embryology, Urmia, Iran.

² Urmia University, Urmia Lake Research Institute, Department of Artemia and Aquaculture, Urmia, Iran.

³ Urmia University, Faculty of Natural Resources, Department of Fisheries, Urmia, Iran.

* Corresponding Author: Tel.: +98 9143482436 ;
E-mail: rasoul_shahrooz@yahoo.com

Received 20 June 2017
Accepted 09 October 2017

Abstract

The present study was performed to elucidate the effects of total replacement of fish oil with vegetable oils on growth performance and foregut histological indices of the rainbow trout. Fishes with average initial weight of 15.10±0.20 g were transferred into 15 (300 L) tanks (50 fishes/tank) and reared for 60 consecutive days using different experimental diets. Kilka fish oil (FO) was fully replaced with different vegetable oil sources including canola oil (CO), safflower oil (SO), linseed oil (LO) and a mixture (CSLO) of CO (40%), SO (30%) and LO (30%) as dietary lipid sources. The samples were fixed at 10% neutral-buffered formalin and paraffin sections were prepared and stained with hematoxylin and eosin and periodic acid-Schiff methods. Growth performances in CO and CSLO groups were better than other groups. Moreover, in these groups, the number of goblet cells was decreased; however thickness and height of intestinal folds and thickness of tunica mucosa and tunica sub-mucosa were increased in comparison to FO group. Overall, performance and histological findings did not show any negative effect due to canola and mixed vegetable oils feeding compared to FO group.

Keywords: Fish oil, vegetable oil, histology, foregut, rainbow trout.

Introduction

Fish oil is the main material used in the formulation of fish feeds. Due to the expansion of aquaculture industry, fisheries will not be able to sustain the aquaculture needs for not too distant future. The global request of fishmeal for aqua feeds may exceed in the next decade. Aquaculture production is expected to extend as a source of fish products for consumption (Tidwell & Allan, 2001). Fish feed replacements in rainbow trout (*Oncorhynchus mykiss*) have been investigated for many years and more attention has been paid to this issue as fishmeal and aquaculture production costs are increasing (Gatlin *et al.*, 2007). In line with that, some alternatives should be introduced instead of marine materials in fish feeds. Several studies have investigated the replacement of fish oil by vegetable oils in fish feed. Partial replacement of fish oils by vegetable oils such as rapeseed, soya bean, linseed and palm oils in fish feeds did not show negative impacts on growth and survival of Atlantic salmon (Rosenlund, Obach, Sandberg, Standal, & Tveit, 2001), brook char (Guillou, Soucy, Khalil, & Adambounou, 1995), gilthead sea bream and European sea bass (Izquierdo *et al.*, 2003) and

rainbow trout (Greene & Selivonchick, 1990; Caballero *et al.*, 2002). Fatty acid (FA) composition of fish lipids generally reflects the FA profile of the diets (Watanabe, 1982). Vegetable oils contain higher levels of saturated and n-6 polyunsaturated fatty acids (PUFA) than fish oil which is richer in n-3 PUFA, mainly eicosapentaenoic and docosahexaenoic acids and long-chain monounsaturated fatty acids. Lipid deposition in fish tissues involves in several metabolic processes including lipogenesis, lipid transport by lipoproteins, tissue lipid uptake (mediated by lipoprotein lipase) and lipids storage (Sheridan, 1988; Tocher, 2003).

Changes in dietary FA composition have been reported to affect FA composition of fish lipids storage and cell membranes in hepatic (Kjaer *et al.*, 2008; Fountoulaki, Alexis, Nengas, & Venou, 2005; Castro *et al.*, 2015), intestinal (Caballero *et al.*, 2003; Ruyter, Moya-Falcón, Rosenlund, & Vegusdal, 2006) and digestive tract tissues (Olsen, Myklebust, Kaino, & Ringo, 1999; Moldal *et al.*, 2014).

Replacement of fish oil with vegetable oils in fish diets can cause histological changes in fish intestinal tissue affecting digestion and absorption processes. Accordingly, in Arctic char (*Salvelinus alpinus*), fed linseed oil (LO) containing high levels

of alpha-linolenic acid, accumulations of fat droplets in enterocytes of pyloric appendages and midgut were observed previously (Olsen, Myklebust, Ringo, & Mayhew, 2000). These changes in alimentary tract can accommodate transport and metabolism of fat in the body and decrease protein and fat digestion (Francis, Turchini, Jones, & De Silva, 2007). In the aquaculture industry, problems in fish oil availability and cost lead to an urgent concern to replace it by more readily available, cheaper and sustainable alternatives such as vegetable oils. This study was conducted to investigate the effects of fish oil replacement with vegetable oils on growth performance and histological structure of foregut in rainbow trout.

Materials and Methods

Fish and Experimental Design

Fish were purchased from a local trout farm and acclimated for 2 weeks during which they were fed commercial diet. Forty healthy fishes with average weight of 15.10 ± 0.20 g were stocked in 15 polyethylene tanks (300 L) supplied with fresh water at a flow rate of 7.50 L min^{-1} . Light/dark cycle was 12 L: 12 D. Water quality parameters were monitored daily for each tank and pH, temperature and dissolved oxygen were maintained at 7.30-7.70, 14-15°C and $6.80\text{-}7.50 \text{ mg L}^{-1}$, respectively.

Experimental Diets

Five experimental diets with similar protein, lipid and energy contents were formulated to contain different vegetable oil sources to replace fish oil (Table 1).

Group 1 (Control) diet contained only Kilka oil (*Clupeonella* sp.), (FO). Group 2 diet contained canola oil (CO) with high levels of oleic acid 18:1n-9. Group 3 diet contained safflower oil (SO) with high levels of linoleic acid 18:2n-6. Group 4 diet contained LO containing high levels of linolenic acid 18:3n-3. Group 5 diet contained a mixture of CO (40%), SO (30%) and LO (30%), designed to provide moderate amount of 18:1n-9, 18:2n-6 and 18:3n-3 FAs (CSLO).

Growth Parameters

Fish meal was defatted three times using a 2:1 mixture of hexane and ethanol (400 mL 100 g^{-1} fish meal), (Dufresne, Fouquet, Forsyth, & Tittlemier, 2007) and used as primary sources of protein in experimental diets. Briefly, all dry ingredients as listed in Table 1 were thoroughly mixed in a mixer. Oil was then added and thoroughly mixed for 5 min and moistened by adding cold distilled water until stiff dough yielded. The wet dough was grinded and converted to strands (3 mm in diameter) using a meat grinder. The strands were dried at $50 \text{ }^\circ\text{C}$ for 8 h using an oven. Afterwards, they were manually crumbled

Table 1. Ingredient and proximate composition of experimental diets

Ingredients (g kg ⁻¹ diet)	Dietary treatment				
	FO	CO	SO	LO	CSLO
Fish meal (defatted)	540	540	540	540	540
Soybean meal	100	100	100	100	100
Fish oil	143	-	-	-	-
Canola oil	-	143	-	-	-
Safflower oil	-	-	143	-	-
Linseed oil	-	-	-	143	-
Vegetable oil ¹	-	-	-	-	143
Blood meal	40	40	40	40	40
Wheat meal	70	70	70	70	70
Wheat starch	60	60	60	60	60
Vitamin premix ²	15	15	15	15	15
Mineral premix ³	10	10	10	10	10
L-methionine	10	10	10	10	10
L-lysine	2	2	2	2	2
Di-calcium phosphate	5	5	5	5	5
Calcium carbonate	5	5	5	5	5
Moisture	8.1	7.6	7.8	8.2	7.7
Crude protein	47.2	46.9	46.8	47.1	47
Crude lipid	14.9	14.9	15.1	15	15.1
Crude starch	11.9	12	11.8	11.9	12.1
Gross energy (kcal/g) ⁴	4.55	4.54	4.54	4.56	4.57

¹Blend vegetable oil: was formulated using canola oil (40%), linseed oil (30%) and safflower oil (30%).

²Vitamin mixture: (mg or IU/kg of diet) Vitamin A (as acetate) 1600000 IU; vitamin D3, 400000 IU; choline chloride, 12000; niacin, 4000; riboflavin, 8000; pyridoxine, 4000; folic acid, 2000; vitamin B12, 8000; biotin, 1; inositol, 20000; vitamin C, 60000; vitamin H2, 2.4; vitamin B2, 8000; vitamin K3, 2000; vitamin E, 40000.

³Mineral mixture (g/kg): zinc, 12.5 g; iron, 26 g; manganese, 15.8 g; copper, 4.2 g; cobalt, 0.48 g; selenium, 2 g; iodine, 1 g.

⁴Calculated on the basis of 5.64, 9.43, and 4.11 (kcal/g diet) for protein, fat, and carbohydrate, respectively.²⁶

into appropriate size and saved. Pellets were stored at 4 °C during the experiment. Fish were fed three times per day at 3% body weight for 8 weeks.

Histological Preparation

After 8 weeks, all fishes were euthanized by clove oil that was used for rapid induction times and consistent anesthesia in fish compared to other anesthetics. Therefore, in this research clove oil has been used at a dose of 40 mg/l for fish anesthesia before tissue samples collection (Aydın, Akbulut, Küçük, & Kumlu, 2015). Foregut samples from six fishes per tank were taken, fixed in 10% buffered formalin, dehydrated in a graded ethanol series and embedded in paraffin. Sections (6 µm in thickness) were stained with periodic acid-Schiff (PAS) method for goblet cells analyses and hematoxylin and eosin (H & E) technique for histomorphometric studies and observed at light microscopy (Olympus model BH-2), (Gretchen, 1979). Histomorphometrical studies included measurement of length and width of intestinal folds, thickness of *Tunica mucosa*, *Tunica compactum*, *Tunica submucosa* and *Tunica muscularis*, height of mucosal epithelial cells and

number of goblet cells. All of these evaluations were performed by graded objective lens in three regions for each stained tissue section. Goblet cells were counted in 100 µm length of intestinal mucosa (Figure 1).

Statistical Evaluation

The results were analyzed using one-way ANOVA. Levene and Shapiro-Wilk tests were also used for analyses of homogeneity of variances and normal distribution. Comparison among the groups was made using Bonferroni's test at confidence level of $P < 0.05$. All statistical analyses were conducted using SPSS (version 16) software (Shapiro & Wilk, 1965).

Results

Growth Indices

Growth parameters of fishes in different experimental groups are presented in Table 2. The results revealed that final weight indices in fishes with 100% replacement of fish oil with CO and compound

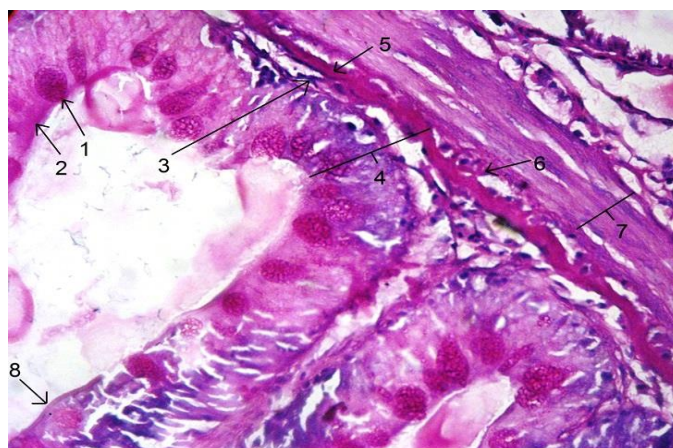


Figure 1. Histostructure of foregut in rainbow trout representing histomorphometrical parameters analyzed in this study. 1- Goblet cell. 2- Simple columnar epithelium and absorptive cell. 3- *Lamina propria*. 4- *Tunica mucosa*. 5- *Tunica compactum*. 6- *Tunica sub-mucosa*. 7- *Tunica muscularis*. 8- Intestinal fold. PAS staining method, 400×.

Table 2. Growth indices of rainbow trout fed experimental diets for 60 days (n=9 fish/tank)

Performance parameters	Dietary treatment ¹				
	FO	CO	SO	LO	CSLO
Initial body weight (g)	15.1±0.2 ^a	15.2±0.1 ^a	15.2±0.1 ^a	15.4±0.2 ^a	15.1±0.2 ^a
Final body weight (g)	69.9±2.3 ^a	69.6±0.4 ^a	58.2±0.5 ^b	61.5±2.5 ^b	68.2±2.2 ^a
Weight Gain (g/fish)	54.8±2.2 ^a	54.4±0.2 ^a	43.0±0.4 ^b	46.1±2.3 ^b	53.1±2.1 ^a
Feed intake (g/fish)	55.4±7.8 ^{ab}	49.9±0.3 ^a	38.8±3.8 ^{ab}	39.4±3.9 ^{bcd}	54.0±6.0 ^{abc}
FCR ²	1.01±0.03 ^b	0.98±0.03 ^b	1.2±0.05 ^a	1.2±0.01 ^a	1.02±0.04 ^b
DGR ³	2.88±0.07 ^a	2.87±0.01 ^a	2.45±0.01 ^b	2.55±0.07 ^b	2.83±0.08 ^a
SGR ⁴	1.17±0.02 ^a	1.16±0.01 ^a	1.02±0.01 ^b	1.05±0.02 ^b	1.14±0.03 ^a
HIS ⁵	1.51±0.02 ^{bc}	1.47±0.04 ^c	1.57±0.07 ^b	1.50±0.03 ^{bc}	1.75±0.06 ^a
VSI ⁶	15.2±1.0 ^a	11.2±0.2 ^c	15.9±0.3 ^a	13.7±0.9 ^b	16.1±0.6 ^a
CF ⁷	1.08±0.03 ^b	1.22±0.02 ^a	1.20±0.03 ^a	1.17±0.02 ^a	1.20±0.09 ^a

vegetable oils in CSLO group are not significantly different from FO group ($P>0.05$). While replacement of fish oil with SO and LO caused a significant decrease in weight indices compared to FO group ($P<0.05$).

Histological Findings

The results of intestinal folds height analyses are demonstrated in Figure 2. According to these data, the height of folds in CO and LO experimental groups was significantly higher than FO group ($P<0.05$). Nevertheless, no significant difference was observed between CSLO and FO groups. The diameters of foregut folds in CO, LO and CSLO groups were significantly higher than FO group ($P<0.05$). However, no significant difference was detected between SO and control groups (Figure 3). Thickness of tunica mucosa in CO, SO and CSLO groups was significantly higher than FO group ($P<0.05$), whereas the observed difference between LO and control groups was not significant (Figure 4). *Tunica compactum* in foregut was significantly ($P<0.05$) thinner than control group only in SO and LO groups (Figure 5).

The sub-mucosa in SO and LO groups was significantly thinner than FO group, while it was significantly thicker than FO group in CSLO group ($P<0.05$). No significant difference was found between CO and control groups (Figure 6).

The *Tunica muscularis* in CO and SO groups was significantly thicker than controls, while it was significantly thinner than FO group in CSLO group ($P<0.05$). The differences between LO and control groups were not significant (Figure 7).

The number of goblet cells in SO and LO groups was significantly higher than control group, but it was significantly lower than FO group in CO group ($P<0.05$). No significant differences were detected in the number of goblet cells between CSLO and control groups (Figure 8). Mean height of mucosal epithelium cells in SO and LO groups was significantly higher than control group ($P<0.05$). Moreover, no significant differences were observed among CO, CSLO and control groups (Figure 9).

Discussion

This study was aimed to evaluate the probable negative effects of the replacement of fish oil with vegetable oils in rainbow trout fingerlings diet. The results of present study showed that fish oil can be totally replaced with CO and CSLO without growth indices reduction. These findings strengthened the former idea of fish oil replacement with vegetable oils in rainbow trout feed (Rosenlund *et al.*, 2001; Torstensen *et al.*, 2005; Richard, Kaushik, Larroquet, Panserat, & Corraze, 2006; Drew, Ogunkoya, Janz, & Van Kessel, 2007; Güler and Yildiz, 2011). Intestinal folds proliferation increased absorptive area in CO fed

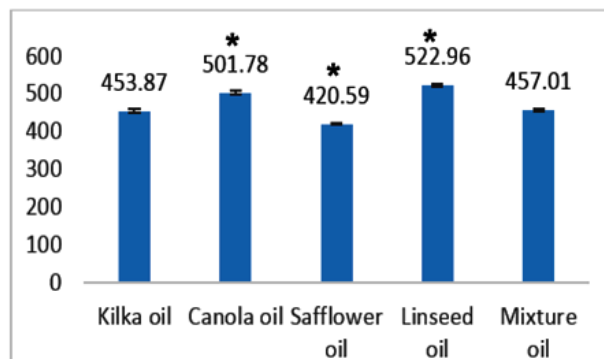


Figure 2. Height of the Folds (Mean±Se, μm).

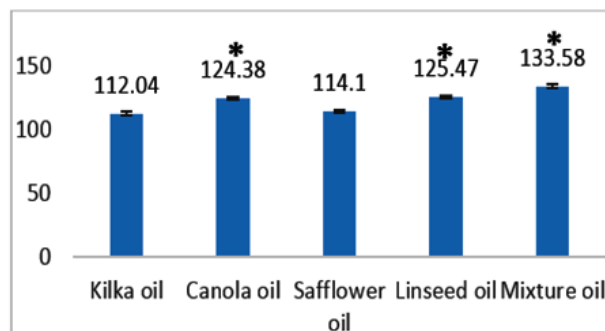


Figure 3. Diameter of the Folds (Mean±Se, μm).

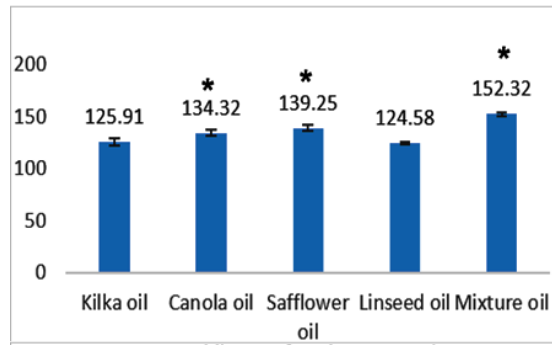


Figure 4. Thickness of *Tunica mucosa* (Mean±Se, µm).

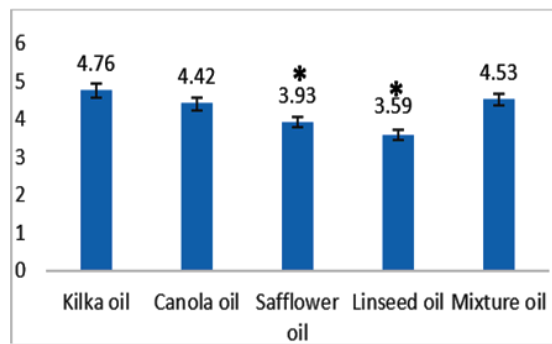


Figure 5. *Tunica compactum* (Mean±Se, µm).

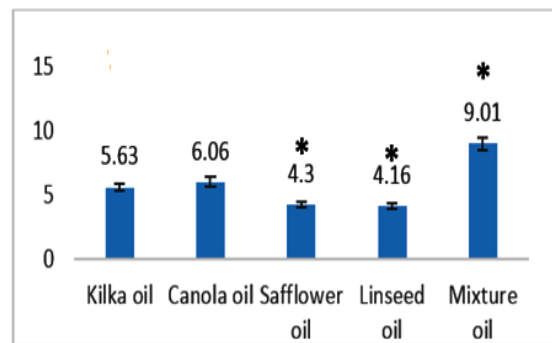


Figure 6. Thickness of *Tunica submucosa* (Mean±Se, µm).

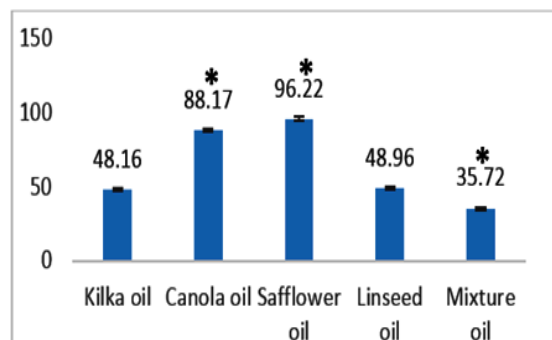


Figure 7. Thickness of *Tunica muscularis* (Mean±Se, µm).

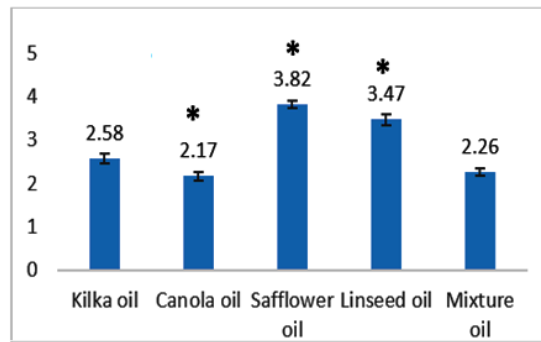


Figure 8. Mean distribution of goblet cells (Mean±Se, in 100µm length).

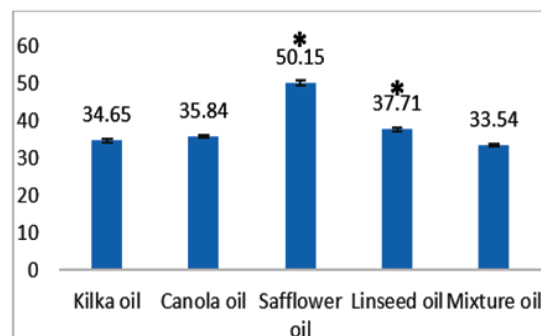


Figure 9. Height of the Epithelial cells (Mean±Se, µm).

fish; however growth indices in CO and CSLO groups were not different from control group. Intestinal folds and tunica mucosa contain connective tissue and blood vessels involving in nutritional absorption and immunological processes (Eurell & Frappier, 2006). Shortened intestinal folds might be associated with reduced intestinal surface and impaired nutrient absorption and growth, but previous reports have suggested that partial substitution of dietary fish oil with vegetable oils does not have any major negative impact on intestinal health of Atlantic salmon (Moldal *et al.*, 2014). Tunica mucosa in CO group was thicker than FO group, nevertheless height and diameter of intestinal folds also increased predominantly in LO group. The height and diameter of villi are found to be related to absorptive properties of mucosa (Murray, Wright, & Goff, 1996). Tunica sub-mucosa contains connective tissue and blood vessels supporting the intestinal functions (Eurell & Frappier, 2006) and here the thickest and thinnest ones were observed in CSLO and LO groups, respectively. *Tunica muscularis* thickness increase results in intestinal contents movement facilitation. This study showed an increase in thickness of *Tunica muscularis* in CO and SO groups, however significant reduction in *Tunica muscularis* thickness compared to control group was observed in CSLO group. The height of epithelium showed significant increases in SO and LO groups in comparison to control group, but significant differences weren't found between other groups and FO group. Epithelium height increase can be attributed to accumulation of lipids in epithelial cells

(Sire, Lutton, & Vernier, 1981), leading to epithelial cells dysfunctions. Goblet cells secrete mucinogen that converts to mucus via water absorption and mucus lubricates intestinal mucosa and enhances food propulsion (Eurell & Frappier, 2006; Khojasteh, 2012). Goblet cells number increase in foregut may reduce food absorption (Young Shin *et al.*, 2000). Our study revealed that number of goblet cells in CO-receiving group was significantly less than control group. It is known that number of goblet cells in many species increases toward the rectum and this may be explained by further need for lubrication in this region (Murray *et al.*, 1996; Khojasteh, Sheikhzadeh, Mohammadnejad, & Azami, 2009). It has been reported that CO as a fish oil alternative has no adverse effects on growth, feed utilization, biometry and FA composition in rainbow trout (Turchini *et al.*, 2013). Finally, it has been suggested that total replacement of fish oil by vegetable oils does not induce adverse changes in fish growth and performance (Benitez-Dorta *et al.*, 2013).

Conclusion

Taken together, the results of this study showed that total replacement of fish oil with vegetable oils causes histological changes in rainbow trout foregut. These alterations can be observed in intestinal folds length and diameter, *Tunica compactum*, *mucosa*, *sub-mucosa* and *muscularis* thicknesses and epithelial cells height as well as goblet cells distribution. It can

be concluded that replacement of fish oil with CO and/or vegetable oils mixture in rainbow trout has not any adverse effects on growth performance indices and foregut histo architecture.

Acknowledgement

The authors express grateful thanks to technicians of Histology and Embryology Laboratories of Veterinary Faculty and Artemia Research Institute of Urmia University, Iran for their kind cooperation.

References

- Aydın, I., Akbulut, B., Küçük, E., & Kumlu, M. (2015). Effects of temperature, fish size and dosage of clove oil on anaesthesia in turbot (*Psetta maxima* Linnaeus, 1758). *Turkish Journal of Fisheries and Aquatic Sciences*, 15, 899-904.
http://dx.doi.org/10.4194/1303-2712-v15_4_13
- Benítez-Dorta, V., Caballero, M.J., Izquierdo, M., Manchado, M., Infante, C., Zamorano, M.J., & Montero, D. (2013). Total substitution of fish oil by vegetable oils in Senegalese sole (*Solea senegalensis*) diets: effects on fish performance, biochemical composition, and expression of some glucocorticoid receptor-related genes. *Fish Physiology and Biochemistry*, 39(2), 335-349.
<http://dx.doi.org/10.1007/s10695-012-9703-4>
- Caballero, M.J., Izquierdo, M.S., Kjorsvik, E., Montero, D., Socorro, J., Fernández, A.J., & Rosenlund, G. (2003). Morphological aspects of intestinal cells from gilthead seabream (*Sparus aurata*) fed diets containing different lipid sources. *Aquaculture*, 225(1), 325-340.
[http://dx.doi.org/10.1016/S0044-8486\(03\)00299-0](http://dx.doi.org/10.1016/S0044-8486(03)00299-0)
- Caballero, M.J., Obach, A., Rosenlund, G., Montero, D., Gisvold, M., & Izquierdo, M.S. (2002). Impact of different dietary lipid sources on growth, lipid digestibility, tissue fatty acid composition and histology of rainbow trout, *Oncorhynchus mykiss*. *Aquaculture*, 214(1), 253-271.
[http://dx.doi.org/10.1016/S0044-8486\(01\)00852-3](http://dx.doi.org/10.1016/S0044-8486(01)00852-3)
- Castro, C., Corraze, G., Pérez-Jiménez, A., Larroquet, L., Cluzeaud, M., Panserat, S., & Oliva-Teles, A. (2015). Dietary carbohydrate and lipid source affect cholesterol metabolism of European sea bass (*Dicentrarchus labrax*) juveniles. *British Journal of Nutrition*, 114(08), 1143-1156.
<http://dx.doi.org/10.1017/S0007114515002731>
- Drew, M.D., Ogunkoya, A.E., Janz, D.M., & Van Kessel, A.G. (2007). Dietary influence of replacing fish meal and oil with canola protein concentrate and vegetable oils on growth performance, fatty acid composition and organochlorine residues in rainbow trout (*Oncorhynchus mykiss*). *Aquaculture*, 267(1), 260-268.
<http://dx.doi.org/10.1016/j.aquaculture.2007.01.002>
- Dufresne, G., Fouquet, A., Forsyth, D., & Tittlemier, S.A. (2007). Multiresidue determination of quinolone and fluoroquinolone antibiotics in fish and shrimp by liquid chromatography/tandem mass spectrometry. *Journal of AOAC International*, 90(2), 604-612.
- Eurell, J.A., & Frappier, B.L. (2006). Dellmann's Text book of Veterinary Histology. UK, Blackwell., 782 pp.
- Fountoulaki, E., Alexis, M.N., Nengas, I., & Venou, B. (2005). Effect of diet composition on nutrient digestibility and digestive enzyme levels of gilthead sea bream (*Sparus aurata* L.). *Aquaculture Research*, 36(13), 1243-1251.
<http://dx.doi.org/10.1111/j.1365-2109.2005.01232.x>
- Francis, D.S., Turchini, G.M., Jones, P.L., & De Silva, S.S. (2007). Effects of fish oil substitution with a mix blend vegetable oil on nutrient digestibility in Murray cod, *Maccullochella peelii peelii*. *Aquaculture*, 269(1), 447-455.
<http://dx.doi.org/10.1016/j.aquaculture.2007.05.021>
- Gatlin, D.M., Barrows, F.T., Brown, P., Dabrowski, K., Gaylord, T.G., Hardy, R.W., ... & Overturf, K. (2007). Expanding the utilization of sustainable plant products in aquafeeds: a review. *Aquaculture Research*, 38(6), 551-579.
<http://dx.doi.org/10.1111/j.1365-2109.2007.01704.x>
- Greene, D.H., & Selivonchick, D.P. (1990). Effects of dietary vegetable, animal and marine lipids on muscle lipid and hematology of rainbow trout (*Oncorhynchus mykiss*). *Aquaculture*, 89(2), 165-182.
[http://dx.doi.org/10.1016/0044-8486\(90\)90308-A](http://dx.doi.org/10.1016/0044-8486(90)90308-A)
- Gretchen L.H. (1979). Animal Tissue Techniques. San Francisco, USA, WH Freeman., 137-138 pp.
- Guillou, A., Soucy, P., Khalil, M., & Adambounou, L. (1995). Effects of dietary vegetable and marine lipid on growth, muscle fatty acid composition and organoleptic quality of flesh of brook charr (*Salvelinus fontinalis*). *Aquaculture*, 136(3), 351-362.
[http://dx.doi.org/10.1016/0044-8486\(95\)00053-4](http://dx.doi.org/10.1016/0044-8486(95)00053-4)
- Güler, M., & Yildiz, M. (2011). Effects of dietary fish oil replacement by cottonseed oil on growth performance and fatty acid composition of rainbow trout (*Oncorhynchus mykiss*). *Turkish Journal of Veterinary and Animal Sciences*, 35(3), 157-167.
<http://dx.doi.org/10.3906/vet-1002-252>
- Izquierdo, M.S., Obach, A., Arantzamendi, L., Montero, D., Robaina, L., & Rosenlund, G. (2003). Dietary lipid sources for seabream and seabass: growth performance, tissue composition and flesh quality. *Aquaculture Nutrition*, 9(6), 397-407.
<http://dx.doi.org/10.1046/j.1365-2095.2003.00270.x>
- Khojasteh, S.B., Sheikhzadeh, F., Mohammadnejad, D., & Azami, A. (2009). Histological, histochemical and ultrastructural study of the intestine of rainbow trout (*Oncorhynchus mykiss*). *World Applied Sciences Journal*, 6(11), 1525-1531.
- Khojasteh, S.M.B. (2012). The morphology of the post-gastric alimentary canal in teleost fishes: a brief review. *International Journal of Aquatic Science*, 3(2), 71-88.
- Kjaer, M.A., Vegusdal, A., Gjoen, T., Rustan, A.C., Todorčević, M., & Ruyter, B. (2008). Effect of rapeseed oil and dietary n-3 fatty acids on triacylglycerol synthesis and secretion in Atlantic salmon hepatocytes. *Biochimica et Biophysica Acta*, 1781(3), 112-122.
<http://dx.doi.org/10.1016/j.bbali.2007.12.004>
- Moldal, T., Lokka, G., Wiik-Nielsen, J., Austbtf, L., Torstensen, B.E., Rosenlund, G., ... Koppang, E.O. (2014). Substitution of dietary fish oil with plant oils is associated with shortened mid intestinal folds in Atlantic salmon (*Salmo salar*). *BMC Veterinary Research*, 10, 60.
<http://dx.doi.org/10.1186/1746-6148-10-60>
- Murray, H.M., Wright, G.M., & Goff, G.P. (1996). A

- comparative histological and histochemical study of the post-gastric alimentary canal from three species of pleuronectid, the Atlantic halibut, the yellowtail flounder and the winter flounder. *Journal of Fish Biology*, 48(2), 187-206.
<http://dx.doi.org/10.1111/j.1095-8649.1996.tb01112.x>
- Olsen, R.E., Myklebust, R., Kaino, T., & Ringo, E. (1999). Lipid digestibility and ultrastructural changes in the enterocytes of Arctic char (*Salvelinus alpinus* L.) fed linseed oil and soybean lecithin. *Fish Physiology and Biochemistry*, 21(1), 35-44.
<http://dx.doi.org/10.1023/A:1007726615889>
- Olsen, R.E., Myklebust, R., Ringo, E., & Mayhew, T.M. (2000). The influences of dietary linseed oil and saturated fatty acids on caecal enterocytes in Arctic char (*Salvelinus alpinus* L.): a quantitative ultrastructural study. *Fish Physiology and Biochemistry*, 22(3), 207-216.
<http://dx.doi.org/10.1023/A:1007879127182>
- Richard, N., Kaushik, S., Larroquet, L., Panserat, S., & Corraze, G. (2006). Replacing dietary fish oil by vegetable oils has little effect on lipogenesis, lipid transport and tissue lipid uptake in rainbow trout (*Oncorhynchus mykiss*). *British Journal of Nutrition*, 96(2), 299-309.
<http://dx.doi.org/10.1079/BJN20061821>
- Rinchar, J., Czesny, S., & Dabrowski, K. (2007). Influence of lipid class and fatty acid deficiency on survival, growth, and fatty acid composition in rainbow trout juveniles. *Aquaculture*, 264(1), 363-371.
<http://dx.doi.org/10.1016/j.aquaculture.2006.11.024>
- Rosenlund, G., Obach, A., Sandberg, M.G., Standal, H., & Tveit, K. (2001). Effect of alternative lipid sources on long-term growth performance and quality of Atlantic salmon (*Salmo salar* L.). *Aquaculture Research*, 32(s1), 323-328.
<http://dx.doi.org/10.1046/j.1355-557x.2001.00025.x>
- Ruyter, B., Moya-Falcón, C., Rosenlund, G., & Vegusdal, A. (2006). Fat content and morphology of liver and intestine of Atlantic salmon (*Salmo salar*): effects of temperature and dietary soybean oil. *Aquaculture*, 252(2), 441-452.
<http://dx.doi.org/10.1016/j.aquaculture.2005.07.014>
- Shapiro, S.S., & Wilk, M.B. (1965). An analysis of variance test for normality (complete samples). *Biometrika*, 52(3-4), 591-611.
<http://dx.doi.org/10.1093/biomet/52.3-4.591>
- Sheridan, M.A. (1988). Lipid dynamics in fish: aspects of absorption, transportation, deposition and mobilization. *Comparative Biochemistry and Physiology Part B: Comparative Biochemistry*, 90(4), 679-690.
[http://dx.doi.org/10.1016/0305-0491\(88\)90322-7](http://dx.doi.org/10.1016/0305-0491(88)90322-7)
- Sire, M.F., Lutton, C., & Vernier, J.M. (1981). New views on intestinal absorption of lipids in teleostean fishes: an ultrastructural and biochemical study in the rainbow trout. *Journal of Lipid Research*, 22(1), 81-94.
- Tidwell, J.H., & Allan, G.F. (2001). Fish as food: aquaculture's contribution. *EMBO Reports*, 2(11), 958-963.
<http://dx.doi.org/10.1093/embo-reports/kve236>
- Tocher, D.R. (2003). Metabolism and functions of lipids and fatty acids in teleost fish. *Reviews in Fisheries Science*, 11(2), 107-184.
<http://dx.doi.org/10.1080/713610925>
- Torstensen, B.E., Bell, J.G., Rosenlund, G., Henderson, R.J., Graff, I.E., Tocher, D.R., & Sargent, J.R. (2005). Tailoring of Atlantic salmon (*Salmo salar* L.) flesh lipid composition and sensory quality by replacing fish oil with a vegetable oil blend. *Journal of Agricultural and Food Chemistry*, 53(26), 10166-10178.
<http://dx.doi.org/10.1021/jf051308i>
- Turchini, G.M., Moretti, V.M., Hermon, K., Caprino, F., Busetto, M.L., Bellagamba, F., ... & Francis, D.S. (2013). Monola oil versus canola oil as a fish oil replacer in rainbow trout feeds: effects on growth, fatty acid metabolism and final eating quality. *Food Chemistry*, 141(2), 1335-1344.
<http://dx.doi.org/10.1016/j.foodchem.2013.03.069>
- Watanabe, T. (1982). Lipid nutrition in fish. *Comparative Biochemistry and Physiology Part B: Comparative Biochemistry*, 73(1), 3-15.
[http://dx.doi.org/10.1016/0305-0491\(82\)90196-1](http://dx.doi.org/10.1016/0305-0491(82)90196-1)
- Young Shin, C., Chul Kim, K., Jong Lee, W., Jo, M.J., Hwan Park, K., Dalby, R., & Ho Ko, K. (2000). Inhaled ATP causes mucin release from goblet cells of intact rats. *Experimental Lung Research*, 26(1), 1-11.
<http://dx.doi.org/10.1080/019021400269925>